

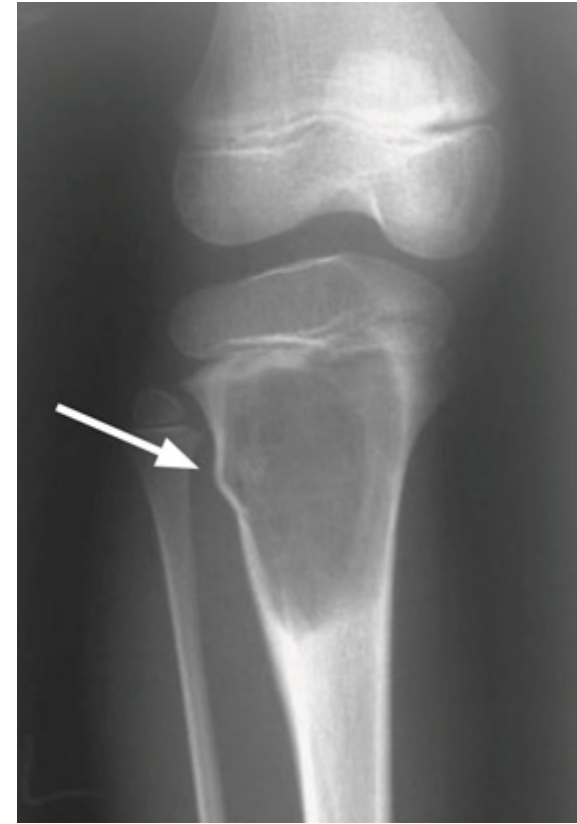

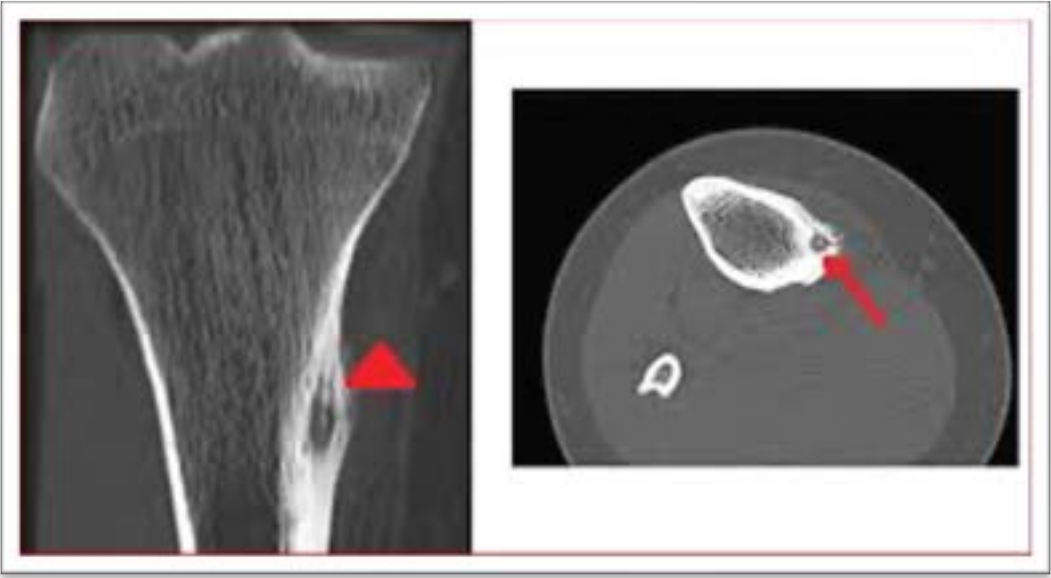
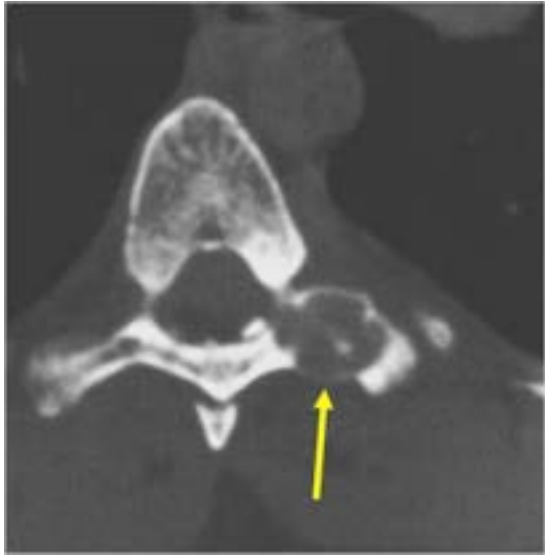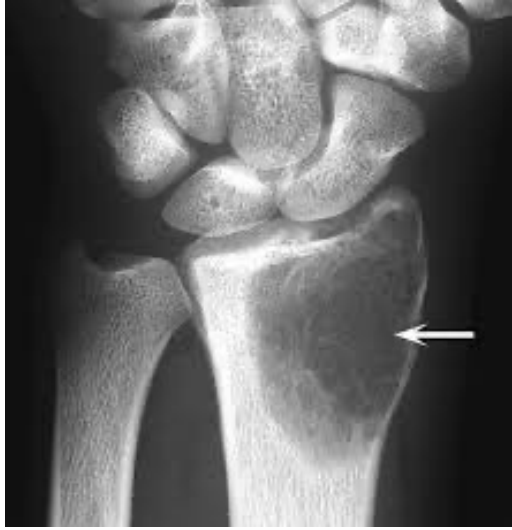BTR Orthopedics - 14-09-2025

Dr. Zainab Vora

1. What is the likely diagnosis based on the given image?

- A. Giant cell tumour
- B. Osteoblastoma
- C. Aneurysmal bone cyst
- D. Osteoid osteoma





2. Earliest way to detect development of compartment syndrome in a patient with cast is:

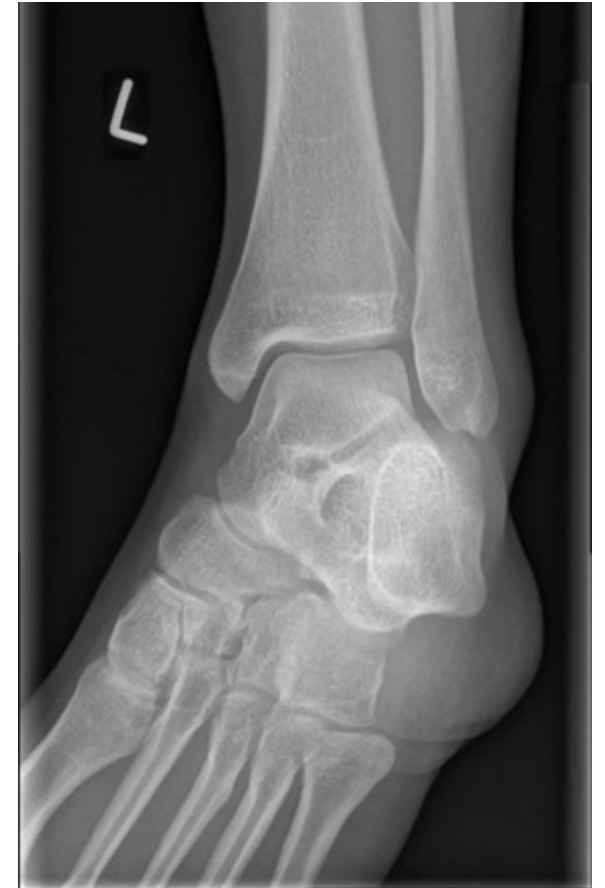- A. Check radial pulse by displacing the cast
- B. Decreased response to analgesia
- C. Change in color of fingers
- D. Weakness in movement of the limb

3. A 28-year-old man presents with a 3-year history of gradually worsening low back pain, bilateral buttock pain, and stiffness. Symptoms are worse in the morning and relieved with stretching and hot showers. He also reports fatigue but denies fever, chills, night sweats, or weight loss. Physical examination reveals a stooped posture and tenderness over the lumbar spine midline and sacroiliac joints. Which of the following pathologic findings is most likely responsible for this patient's symptoms?

- A. Areas of bony erosions and new bone formation
- B. Areas of disorganized trabecular and cortical bone thickening
- C. Disc protrusion and thickening of the ligamentum flavum
- D. Plasma cell infiltrate in bone marrow

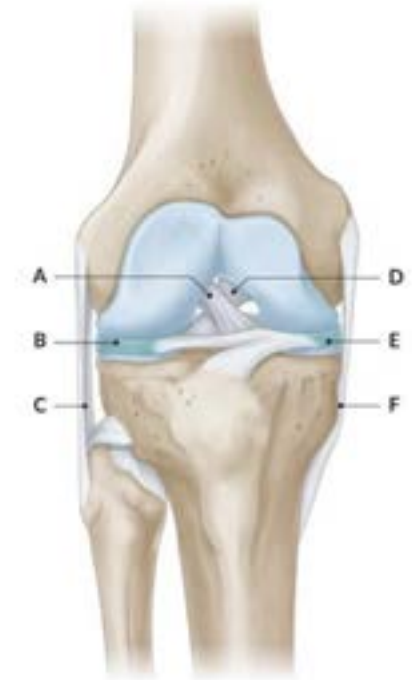4. A 25-year-old woman comes to the emergency department after she awkwardly landed on her foot while playing volleyball. An X-ray of the foot is shown. The physician proceeds to immobilize her foot with a cast. Which of the structures is the most commonly injured in this patient?

- A. Anterior talofibular ligament
- B. Achilles tendon
- C. Posterior talofibular ligament
- D. Peroneus brevis



5. A 27-year-old woman comes to the physician for a follow-up examination. Four days ago, she injured her right knee while playing basketball. Increased laxity of the right knee joint is noted when the knee is flexed to 30° and an inward pressure is applied at lateral thigh with one hand and outward pressure with medial ankle with the other hand. The examination finding in this patient is most likely caused by damage to which of the following structures?

- A. C
- B. F
- C. A
- D. D

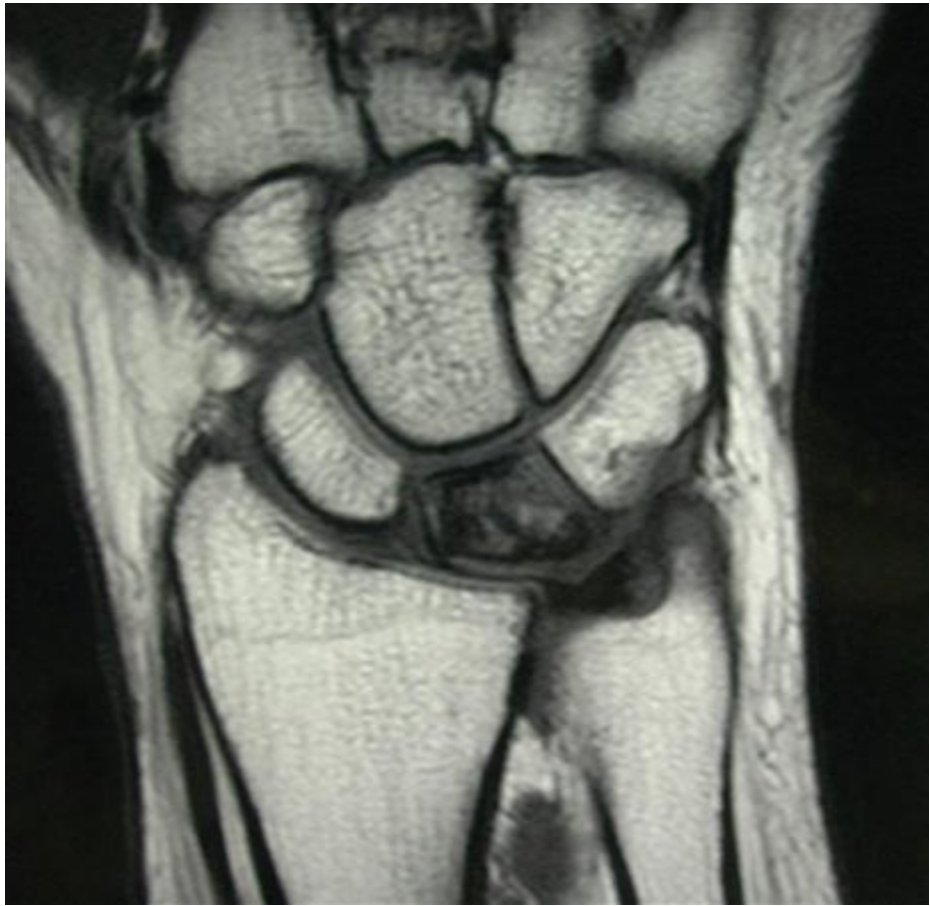

6. A 55-year-old woman comes to the office due to right shoulder pain for 4 months. She reports that the pain has improved since its onset, but now she has trouble with activities such as washing her hair or reaching the upper shelves of the kitchen cabinets. Heating pads and ice packs have not helped. She has had no fever, weight loss, or trauma. Medical history includes hypertension treated with lisinopril and hypothyroidism treated with levothyroxine. On examination, there is mild atrophy of the right deltoid muscle. Active and passive range of motion of the right shoulder is markedly reduced in abduction, flexion, and internal and external rotation compared to the left. Sensation in the upper extremities and strength in the hands and elbows are preserved. Which of the following is the best next step in management of this patient? Options:

- A. Deltoid muscle biopsy
- B. MRI of the cervical spine
- C. Nerve conduction studies
- D. Range-of-motion exercises

7. A 30-year-old woman presents to the physician with right wrist pain after a fall while jogging. Physical examination shows decreased grip strength and tenderness between the tendons of the extensor pollicis longus and extensor pollicis brevis. X-ray of the right wrist shows no abnormalities. This patient is at increased risk for which of the following complications?

- A. Hypesthesia of the hypothenar eminence
- B. Contracture of the palmar aponeurosis
- C. Avascular necrosis of the scaphoid bone
- D. Collapse of the lunate bone

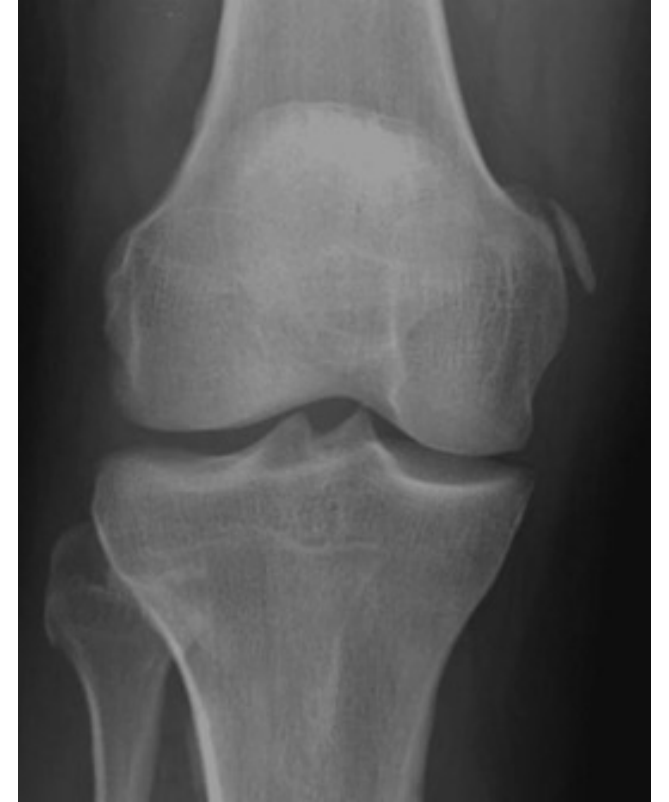

8. A 25-year-old woman visits the doctor with pain and weakness in her right forearm and hand for several months. Two years ago, she had a fracture in her ulnar shaft and a dislocation of her radial head that required surgery. On examination, there is mild tenderness a few centimeters distal to the lateral epicondyle. She has significant weakness when trying to extend her right middle finger and radial deviation on extension of the wrist. Sensation is normal. Which nerve is most likely affected in this patient?

- A. Anterior interosseous nerve
- B. Superficial radial nerve
- C. Posterior interosseous nerve
- D. Ulnar nerve

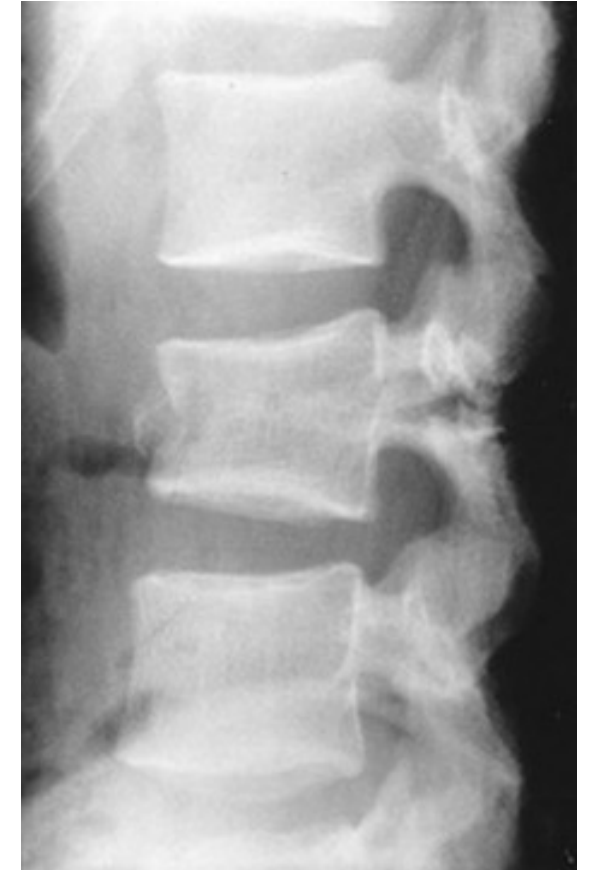9. A 30-year-old male presents to the clinic with left knee pain and instability following a previous injury. Xray is shown below. Which ligament is most likely involved based on this finding?

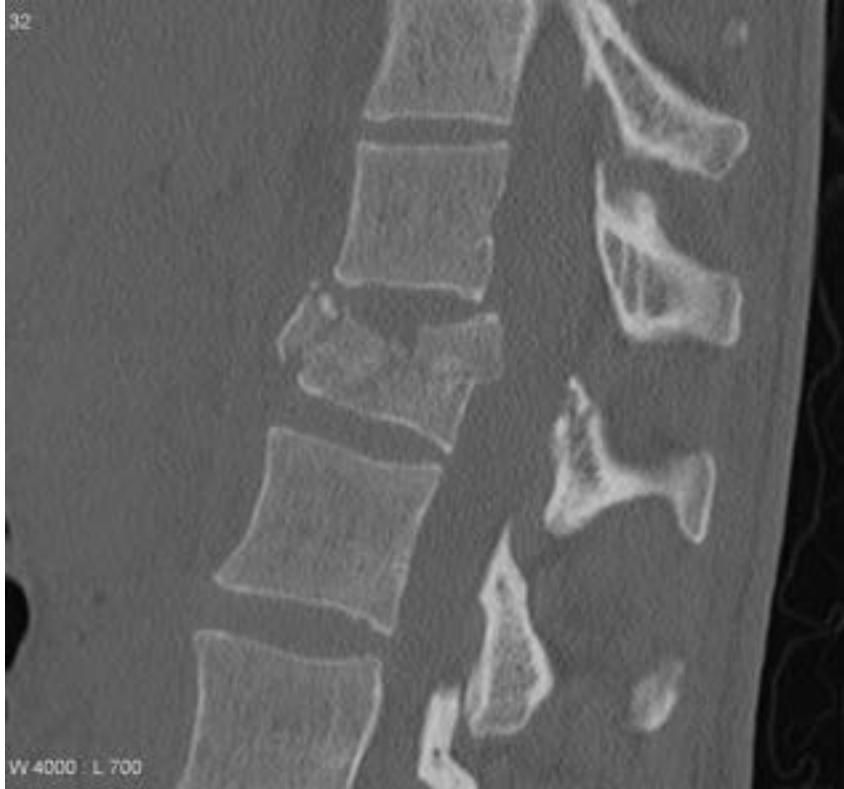- A. ACL
- B. PCL
- C. Lateral meniscus
- D. MCL



10. A patient presented with severe back ache and the following x-ray after an RTA. Diagnose the fracture present.

- A. Burst fracture
- B. Chance fracture
- C. Compression fracture
- D. Fracture of spinous process



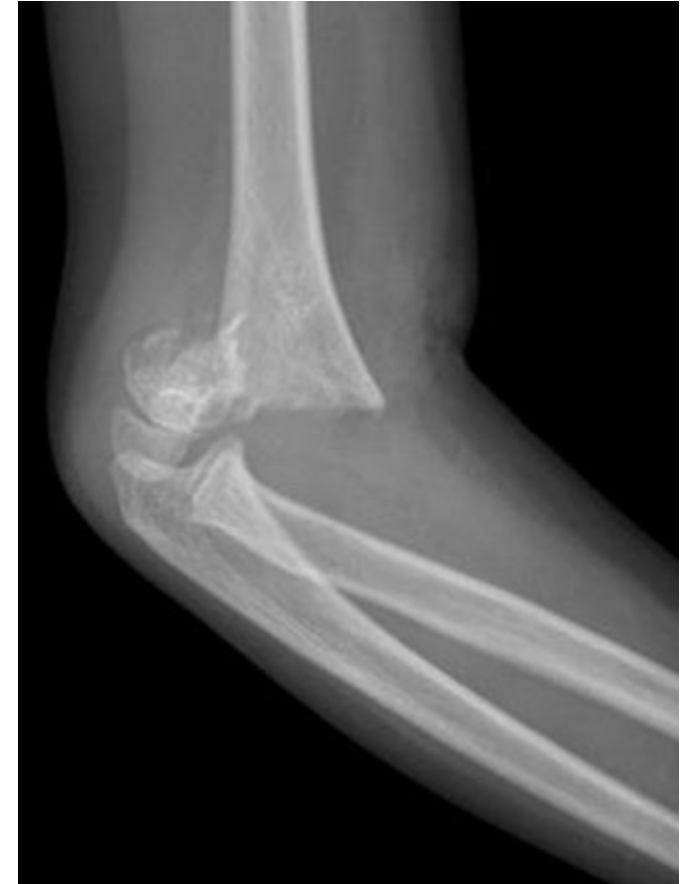

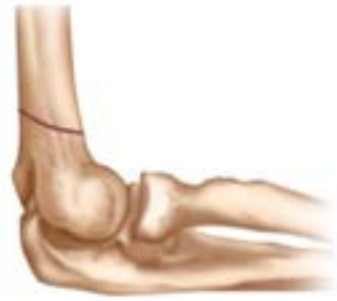11. A 75-year-old woman presents to the clinic after a fall. She complains of right hip and thigh pain. Examination reveals that her right leg is shorter than her left and externally rotated. Which of the following pathological changes is most likely to be present in this patient?

- A. Cortical bone overgrowth and sclerosis due to defective osteoclasts
- B. Impaired mineralization of osteoid and hyperactive osteoblasts
- C. Decreased cortical and trabecular bone mass with normal bone mineralization
- D. Woven and lamellar bone mosaic pattern due to increased osteoclast and osteoblast activity resulting in bone of low quality

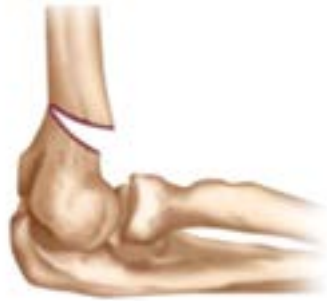12. Identify the classification used and grade of the shown injury in a child

- A. Gartland's classification Type III
- B. Salter-Harris classification Type III
- C. Gartland's classification Type IV
- D. Salter-Harris classification Type IV

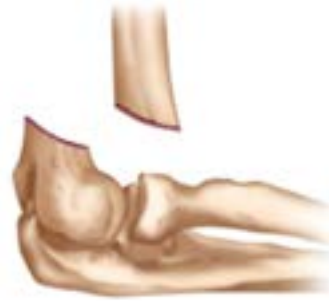



Type I



Type II

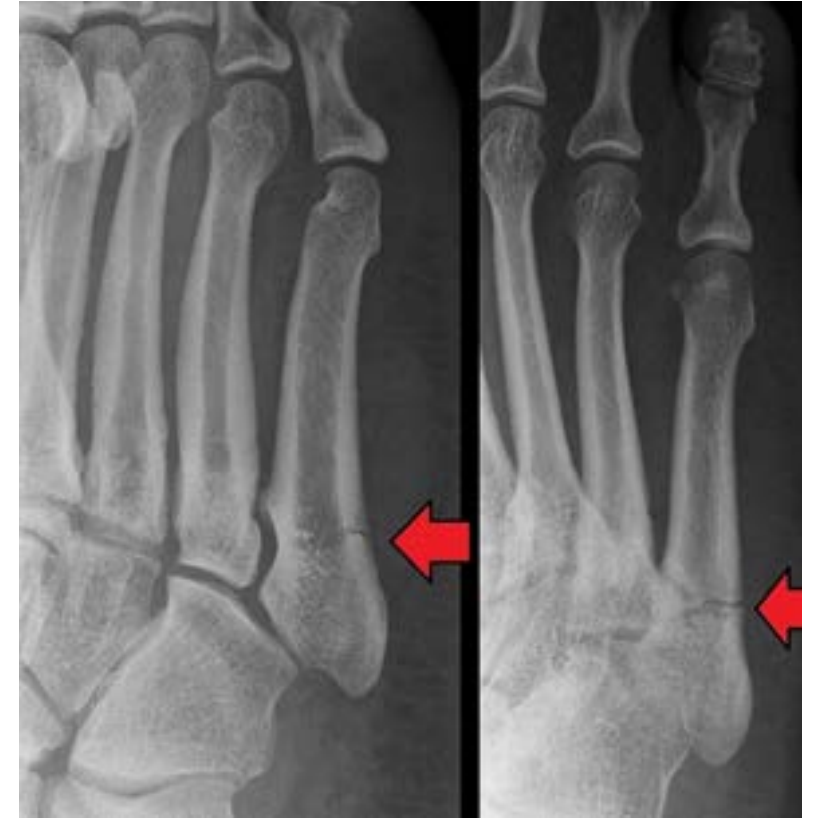

Type III

| | |
|-----------|---|
| Type I | Non-displaced |
| Type II A | Intact posterior cortex, hinged in extension. No rotation or translation. |
| Type II B | Intact posterior cortex, hinged in extension, with some degree of rotational displacement or translation. |
| Type III | Complete displacement. |

13. Identify the fracture and mention the duration of below-knee POP cast applied for the following injury?

- A. Jones fracture; 2-3 weeks
- B. Pseudo-Jones fracture; 3-5 weeks
- C. Jones fracture; 6-8 weeks
- D. Pseudo-Jones fracture; 6-8 weeks

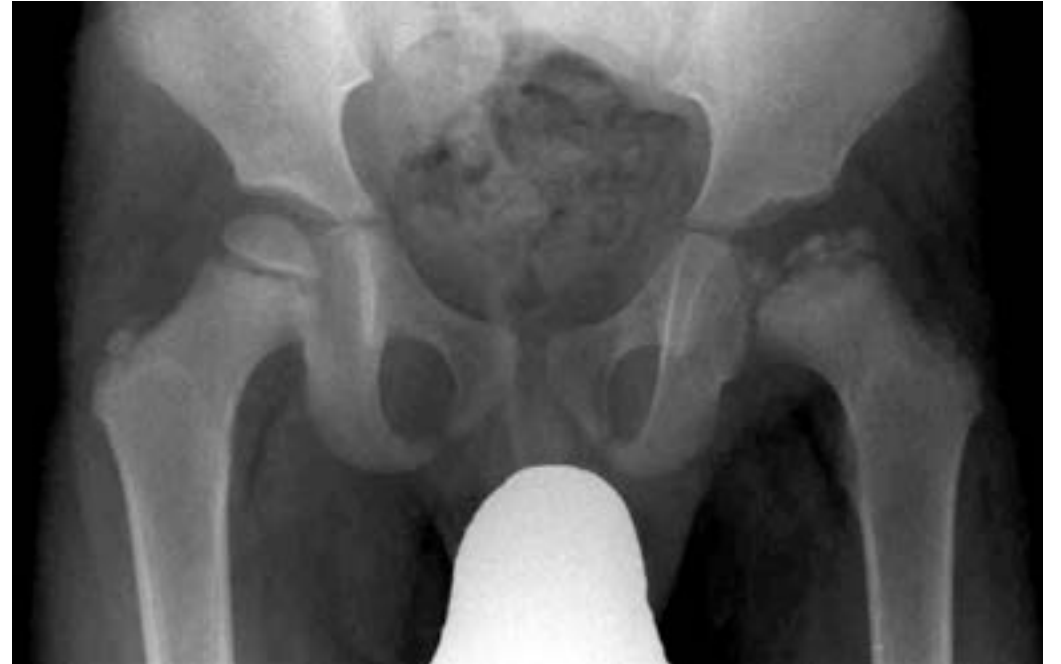

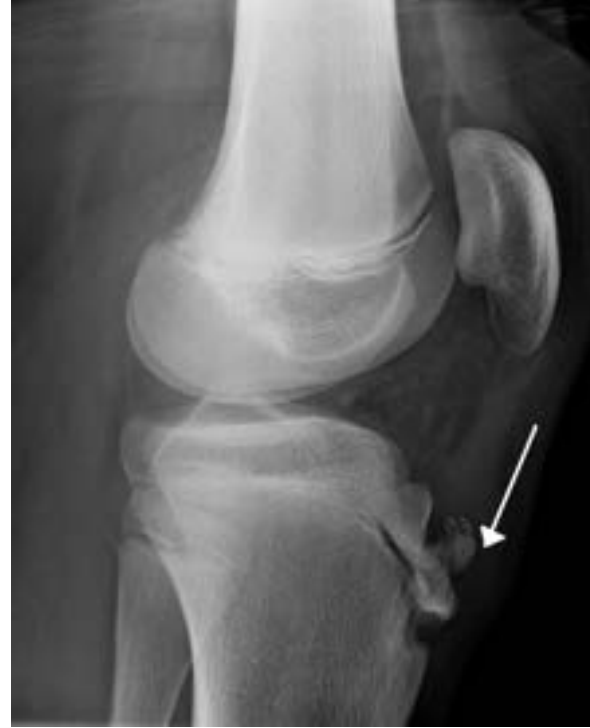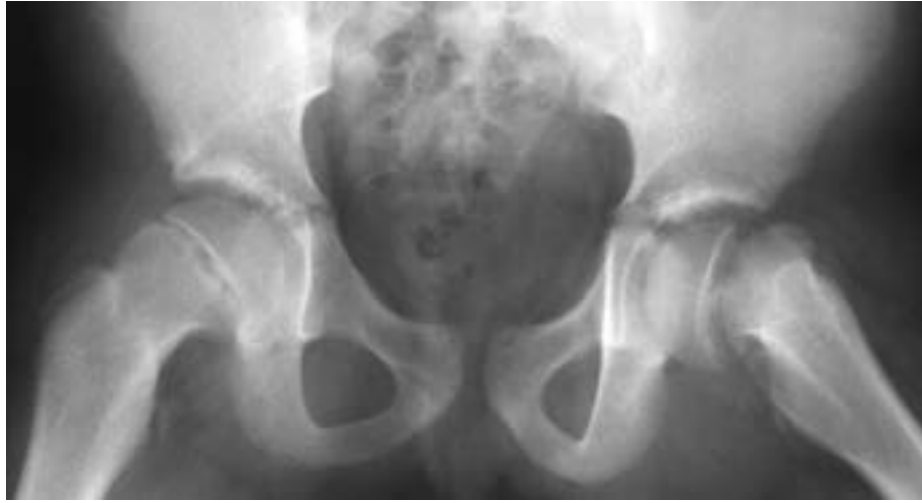14. A 19-year-old male presents with localized bone pain in the tibia. Imaging reveals a small radiolucent lesion surrounded by dense reactive sclerosis. The pain improves with NSAIDs. Which of the following is a histological feature of the most likely diagnosis?

- A. Trabeculae of woven bone surrounded by fibrovascular stroma
- B. Malignant osteoid production with atypical mitoses
- C. Multinucleated giant cells surrounding hemorrhagic spaces
- D. Fibrous tissue with scattered irregular bony trabeculae

15. A 6-year-old boy presents to the clinic with a 2-week history of limping due to right hip pain, which radiates to the knee. The pain increases with walking. He has no history of fever, cough, or recent infections. On examination, there is a restricted range of motion in the right hip during internal rotation and abduction, and pain is elicited during these movements. What is the most likely diagnosis?

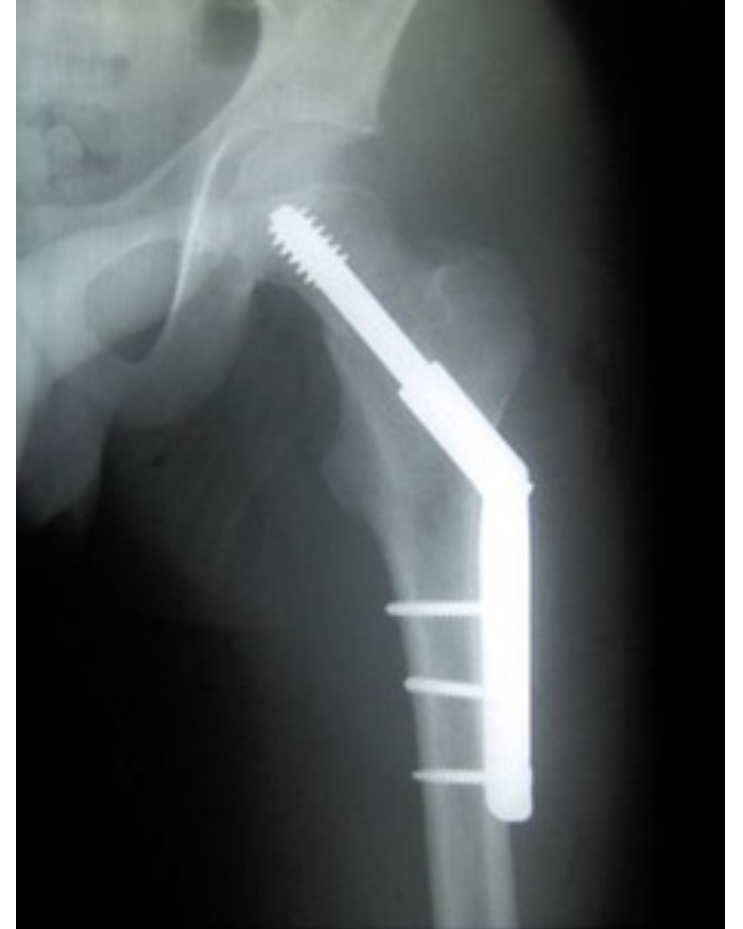- A. Legg-Calvé-Perthes disease
- B. Septic arthritis
- C. Osgood-Schlatter disease
- D. Slipped capital femoral epiphysis





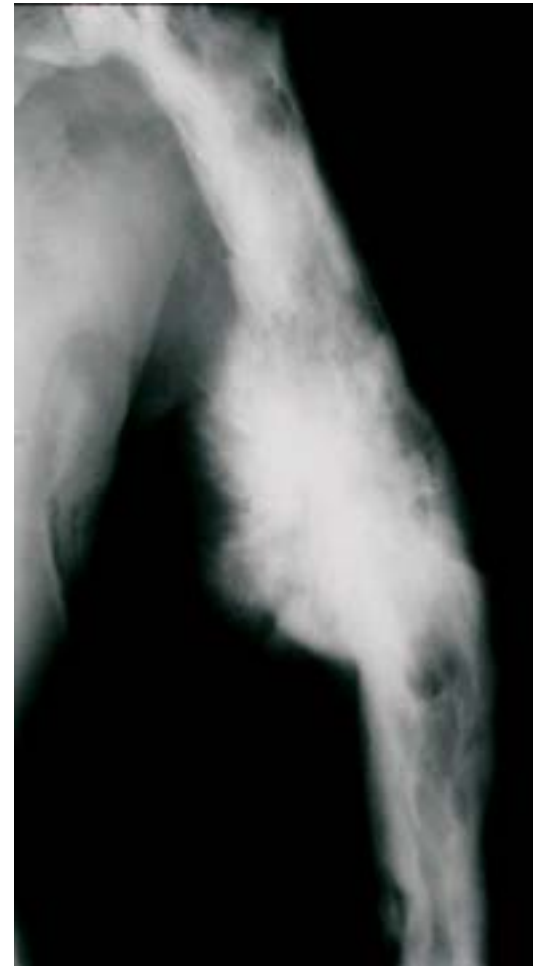16. Identify the implant shown in the image used for treatment of proximal femoral fracture.

- A. Dynamic hip screw
- B. Dynamic condylar plate
- C. Proximal femoral nail
- D. Limited contact condylar plate



17. A 68-year-old man comes to the physician because of a 5-month history of undulating, dull pain in his right leg. Physical examination shows a tender, round mass located above the right knee on the anterior aspect of the thigh. An X-ray of the right thigh is shown. Which of the following is the strongest predisposing factor for this patient's condition?

- A. Hyperparathyroidism
- B. t(11;22) translocation
- C. RB gene mutation
- D. Paget disease of bone



18. A 32-year-old man comes to the physician because of a 6-week history of left shoulder pain, numbness, and tingling in his left hand. He mentions that the symptoms worsen when he raises his arm above his head. He works as a construction worker, frequently lifting heavy tools. Physical examination reveals decreased fine touch in the 4th and 5th fingers of the left hand and weakened grip strength on the left side. Palpation of the neck reveals diffuse pain. The patient's left arm is held in abduction, extension, and external rotation, and he is instructed to turn his head toward it while breathing deeply, causing a decreased radial pulse on the left side. Which of the following is the most likely cause of the patient's findings?

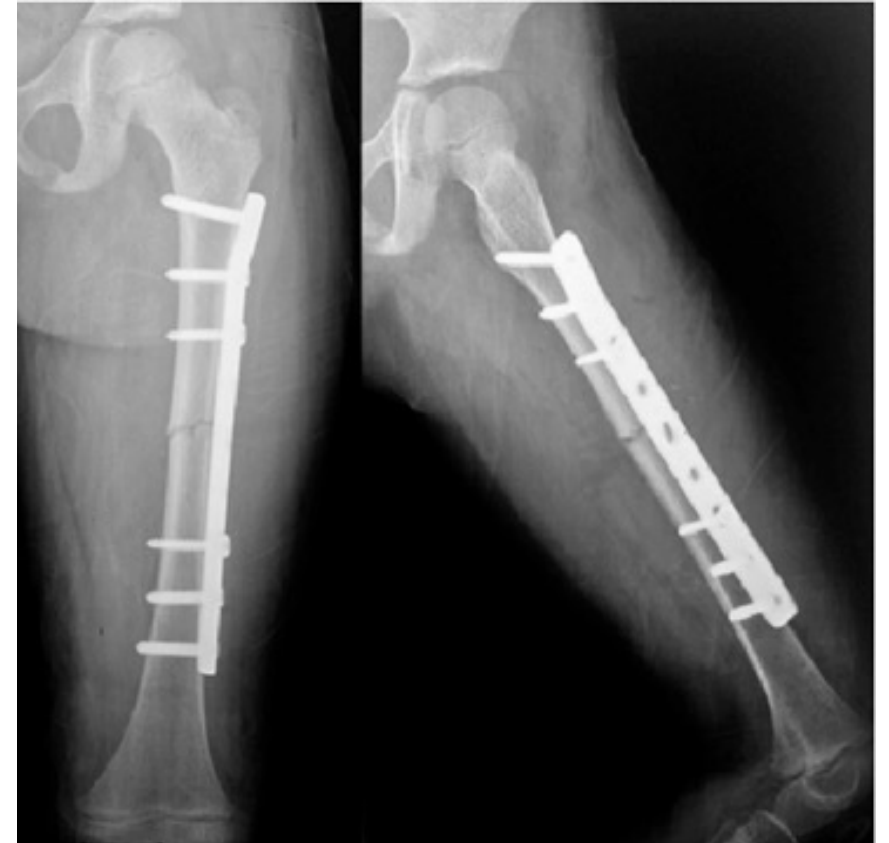- A. Median nerve compression at the wrist
- B. Left rotator cuff tendinopathy
- C. C8 nerve root compression
- D. Anterior scalene muscle hypertrophy

19. A 32-year-old woman is brought to the emergency department 4 hours after being bitten by a venomous snake. Her pulse is 132/min, and her blood pressure is 102/79 mm Hg. Examination shows right lower leg swelling, ecchymosis, and blistering. Right ankle dorsiflexion elicits severe pain. A manometer inserted into the lateral compartment of the lower leg reveals an intracompartmental pressure of 68 mm Hg. In addition to administration of antivenom, the patient undergoes fasciotomy. Two weeks later, she reports difficulty walking. Neurologic examination reveals a loss of sensation over the lower part of the lateral side of the right leg and the dorsum of the right foot. Right foot eversion is 1/5. There is no weakness in dorsiflexion. Which of the following nerves is most likely injured in this patient?

- A. Deep peroneal nerve
- B. Tibial nerve
- C. Superficial peroneal nerve
- D. Saphenous nerve

20. A child sustained a fracture after a fall. The post-op x-ray is shown below. The fracture will heal by which mechanism? (NEET PG 2024)

- A. Creeping substitution
- B. Intramembranous ossification
- C. Primary healing
- D. Secondary healing



Primary bone healing: No callus
Secondary bone healing: Callus +
Callus earliest:
Delayed union:
Non-union:

21. Arrange the following external fixators used for treatment of fracture of tibia in order of increasing stability:

I. Ilizarov

II. Uniplanar frame with one rod

III. Biplanar frame

IV. Uniplanar frame with two rods

A. II, IV, III, I

B. I, III, II, IV

C. II, III, IV, I

D. I, II, III, IV

22. Which of the following is not true about intracapsular fracture of femur neck?

- A. Displacement is less common than extracapsular fractures
- B. Malunion is common complication
- C. Contour of greater trochanter is normal
- D. Tenderness is mainly present over the anterior joint line

23. Identify the correct statements

1. The most common complication of an untreated radial head dislocation is the cubitus valgus deformity at the elbow.

2. Seek kebab surgery / Sofield Miller Osteotomy is performed for Achondroplasia

3. Tartrate-resistant acid phosphatase (TRAP) is elevated in osteoporosis

4. Posterior tibialis tendon is palpable behind the medial malleolus during inversion of the foot

A. 1, 2, 3, 4

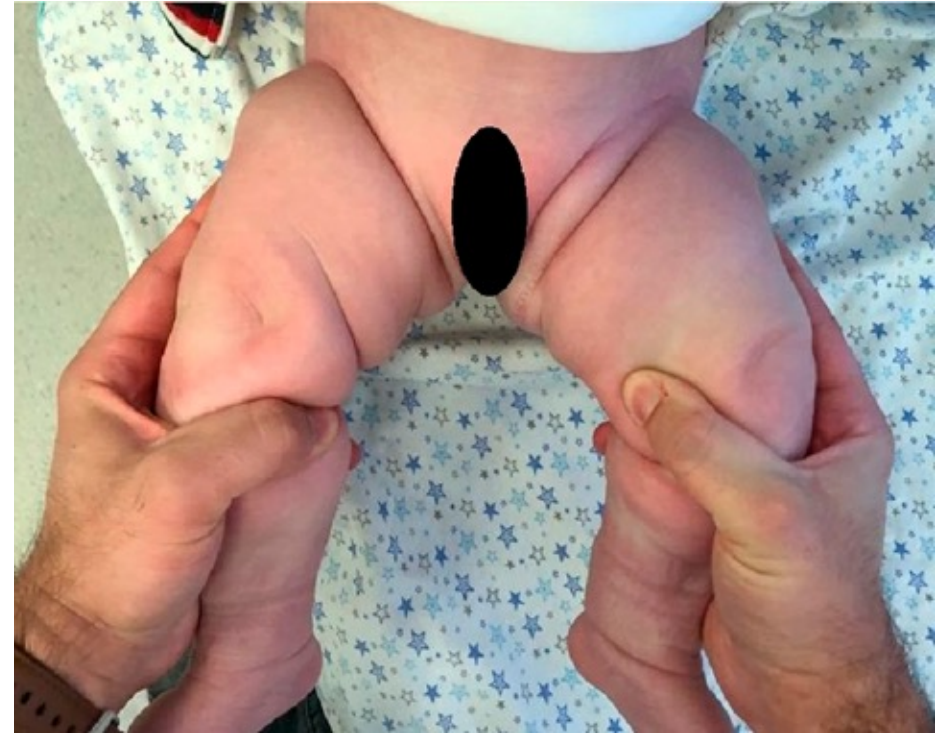B. 1, 3

C. 1, 3, 4

D. 2, 3

24. 1-month-old girl is brought to the OPD for a routine newborn examination. Physical examination is shown below. When supine with the knees flexed, the left knee appears to be inferior to the right knee. Skin examination shows a nonblanching, blue-grey macule with indefinite borders over the sacrum. Which of the following is the most appropriate next step in management of this patient?

- A. Reassurance
- B. Skeletal survey
- C. Ultrasound of hips
- D. X-ray of hips



25. Patient had difficulty in walking upstairs. When he was made to bear weight on right lower limb, the left-sided pelvis dropped down but when he was standing on the left lower limb, the right-sided pelvis moved up. Which of the following is the likely lesion?

- A. Right superior gluteal nerve palsy
- B. Left superior gluteal nerve palsy
- C. Right inferior gluteal nerve palsy
- D. Left inferior gluteal nerve palsy

26. What is the sequence of performing a Thomas test?

I. Passive flexion of affected hip

II. Active flexion of normal hip

III. Measure the flexion angle

IV. Checking for lumbar lordosis

A. I, II, III, IV

B. I, III, II, IV

C. II, III, IV, I

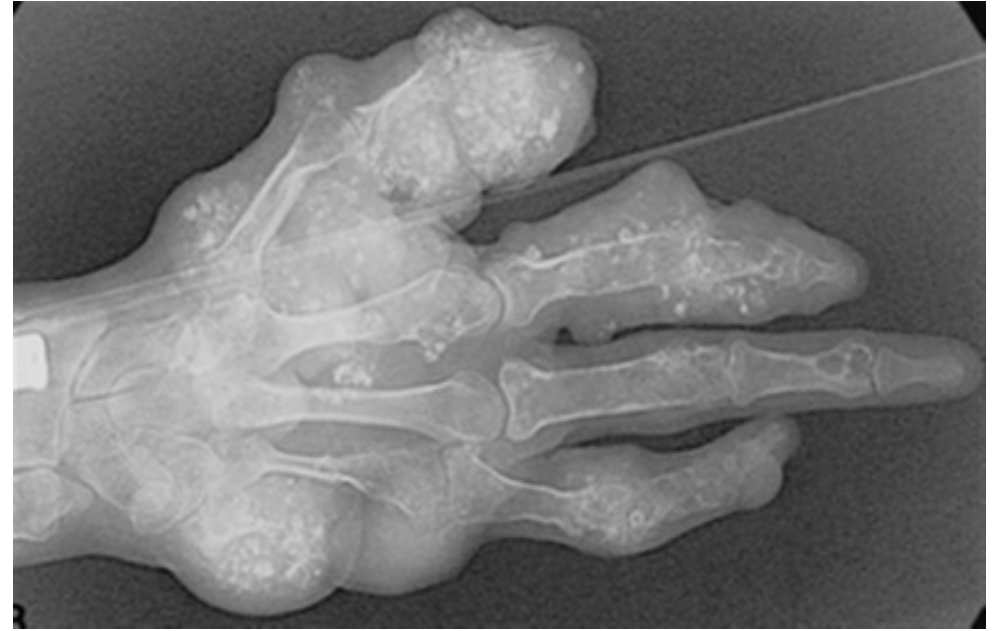
D. IV, II, I, III

27. Most dangerous type of odontoid fracture as per Anderson and D'Alonzo classification and its respective management is:

- A. Type I- immobilization in rigid collar
- B. Type II-screw fixation
- C. Type III-halo vest immobilization
- D. Type IV-open reduction internal fixation

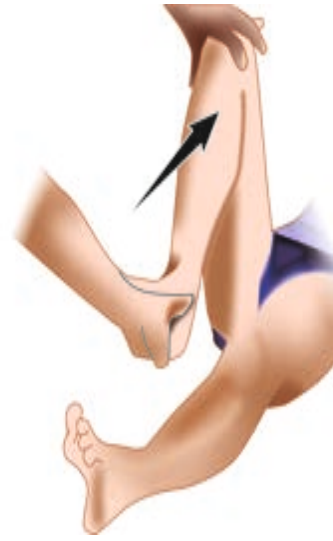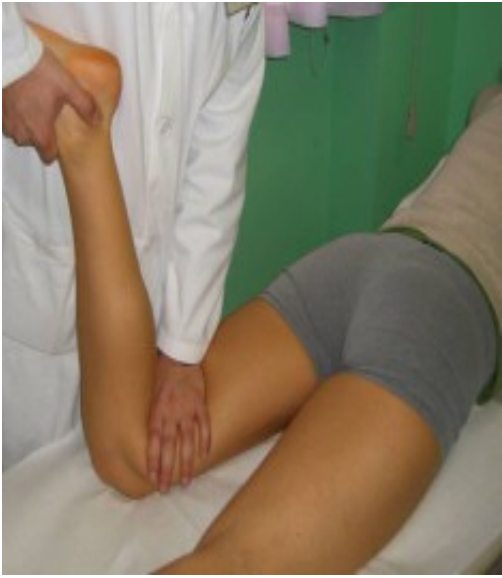28. What is the likely diagnosis based on the images shown?

- A. Mazzabarud syndrome
- B. Ollier disease
- C. Maffucci disease
- D. Osler-Weber-Rendu syndrome



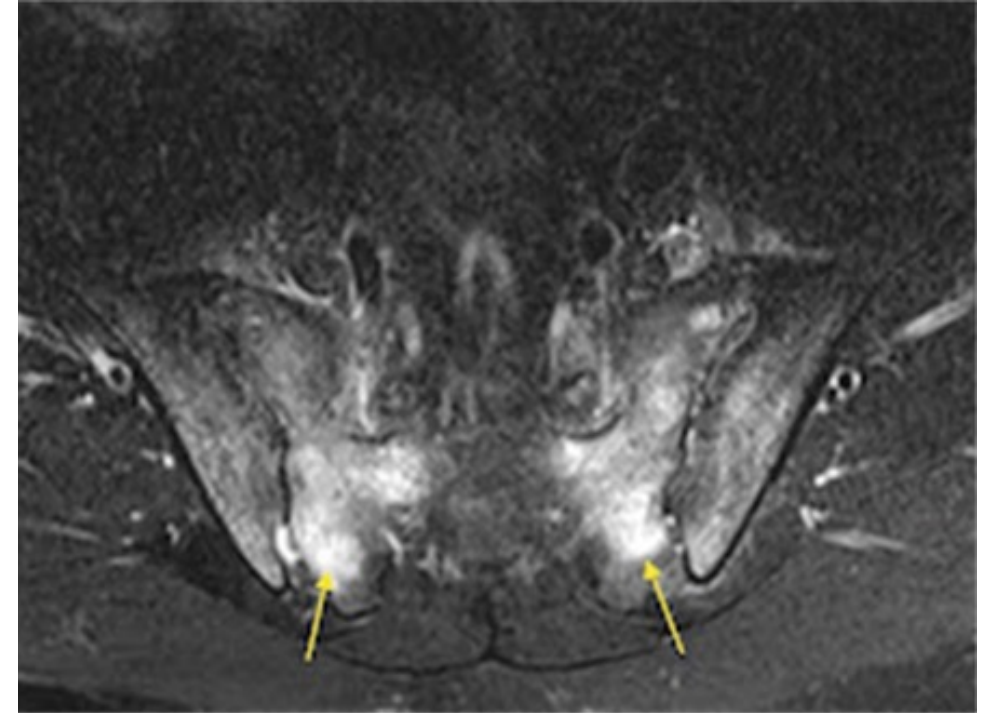
29. 42-year-old woman comes to the AIIMS OPD due to right knee pain for the past 3 days. She was carrying a heavy backpack on a muddy trail when she tripped, twisting her leg. The next morning, she had swelling at the knee and significant medial knee pain with stairs and squatting. Which of the following is most likely to be found on examination of this patient's knee?

- A. Anterior laxity of the tibia relative to the femur
- B. Excessive valgus deviation with lower leg abduction
- C. Painful click during knee extension and external rotation
- D. Tenderness at the medial knee below the joint line



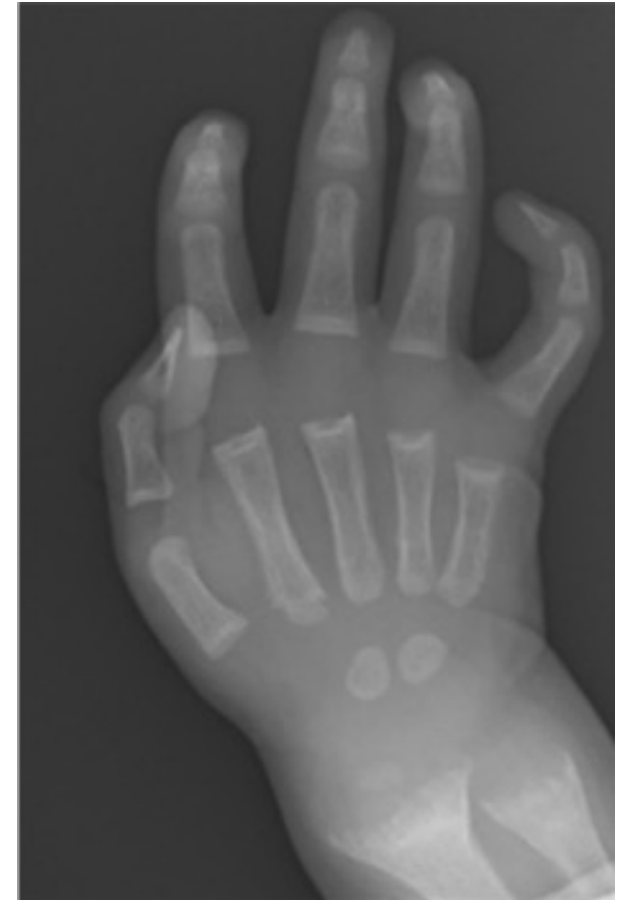30. What other finding would be expected in this 25-year-old male with abnormal pelvis MRI?

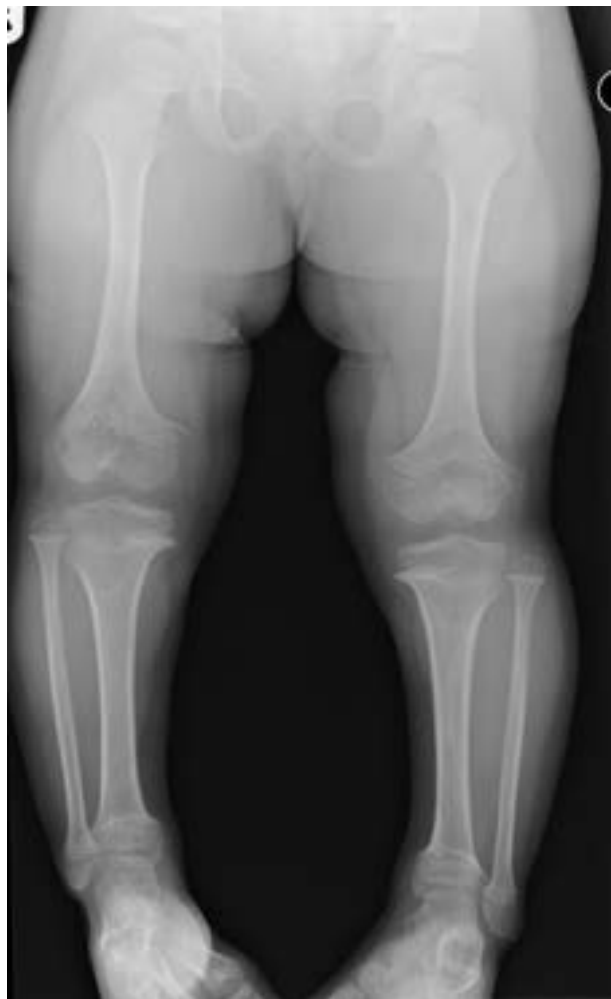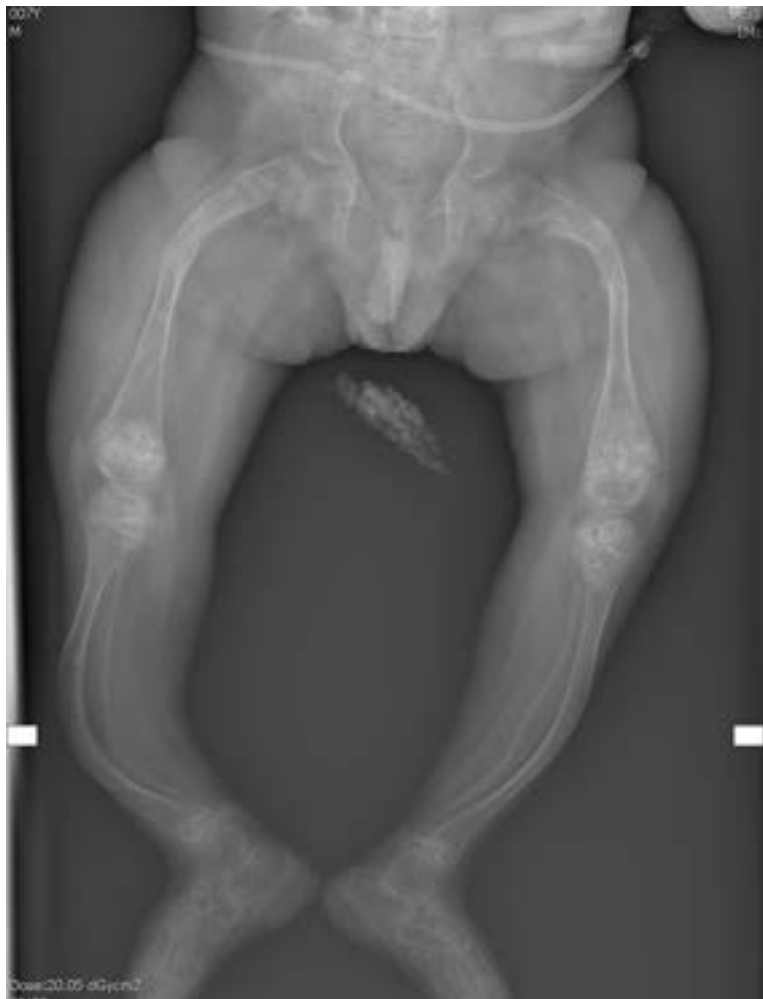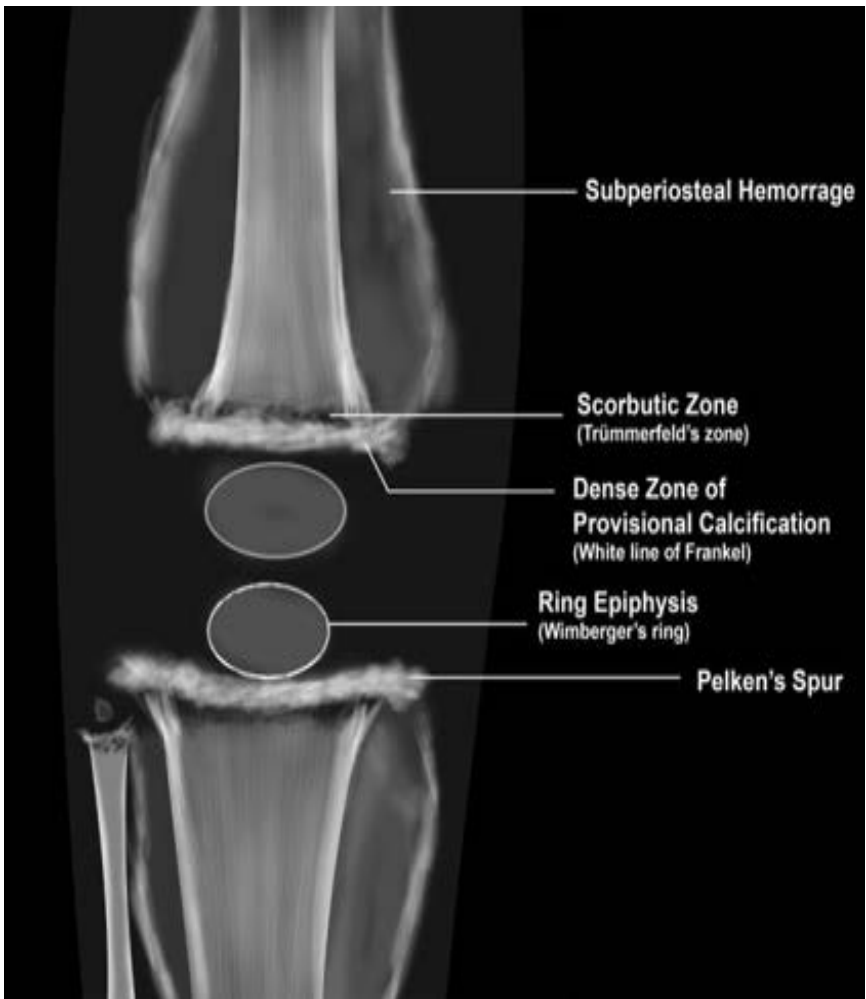
- A. Elevated RF
- B. Acute painful red eye
- C. Atlanto-axial dislocation
- D. IV disc calcification



31. A child presented with difficulty in walking. The wrist radiograph is shown below. What is the diagnosis?

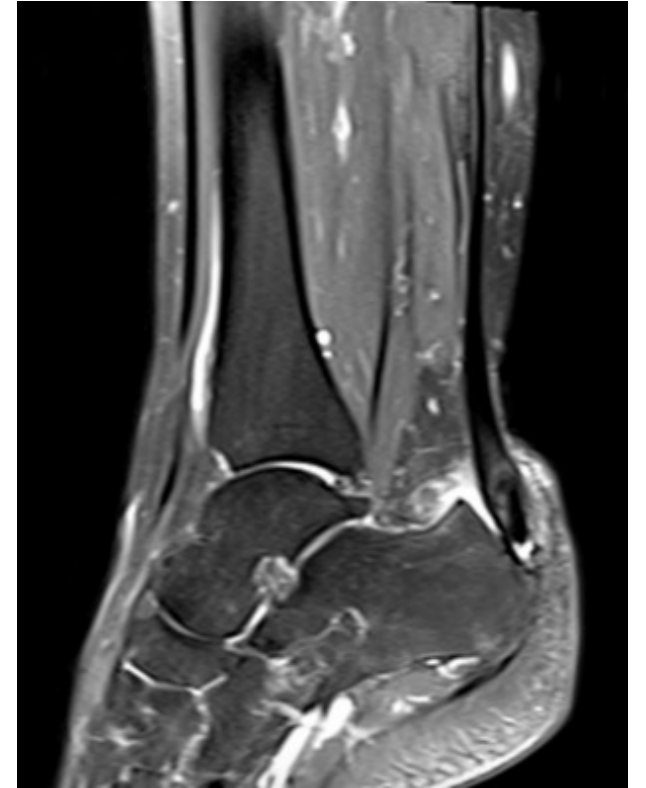
- A. Scurvy
- B. Osteogenesis imperfecta
- C. Rickets
- D. Achondroplasia

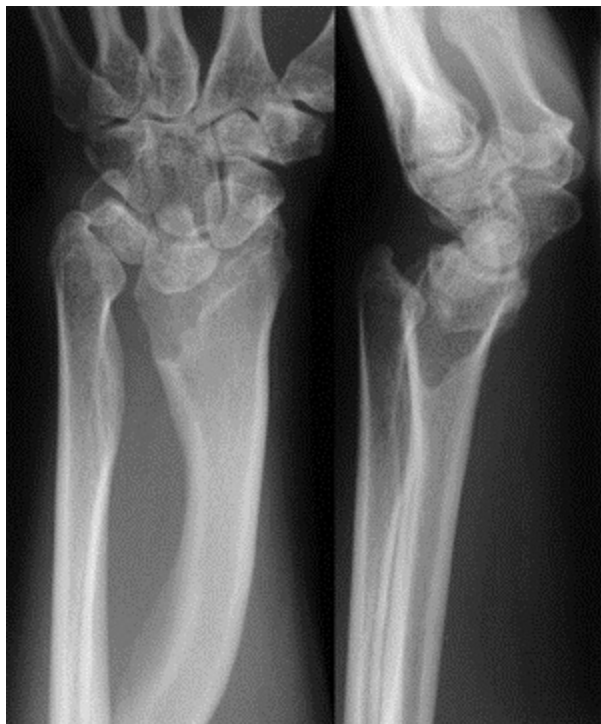



32. A 25-year-old female presents with right heel pain since 3 months. She is a model by profession. There is no history of trauma. What is the likely diagnosis based on the MRI STIR image shown below?

- A. Madelung deformity
- B. Haglund deformity
- C. Plantar fasciitis
- D. Stress fracture





33. A 22-year-old woman comes to the OPD for evaluation of new-onset foot pain. The pain is located at the heel and is most pronounced when she gets up from sitting after a long period of time. She enjoys running every evening for one hour. Direct pressure to the bottom of the heel elicits sharp pain, but mediolateral squeezing of the heel causes no discomfort. Which of the following is the most likely etiology of the patient's foot pain?

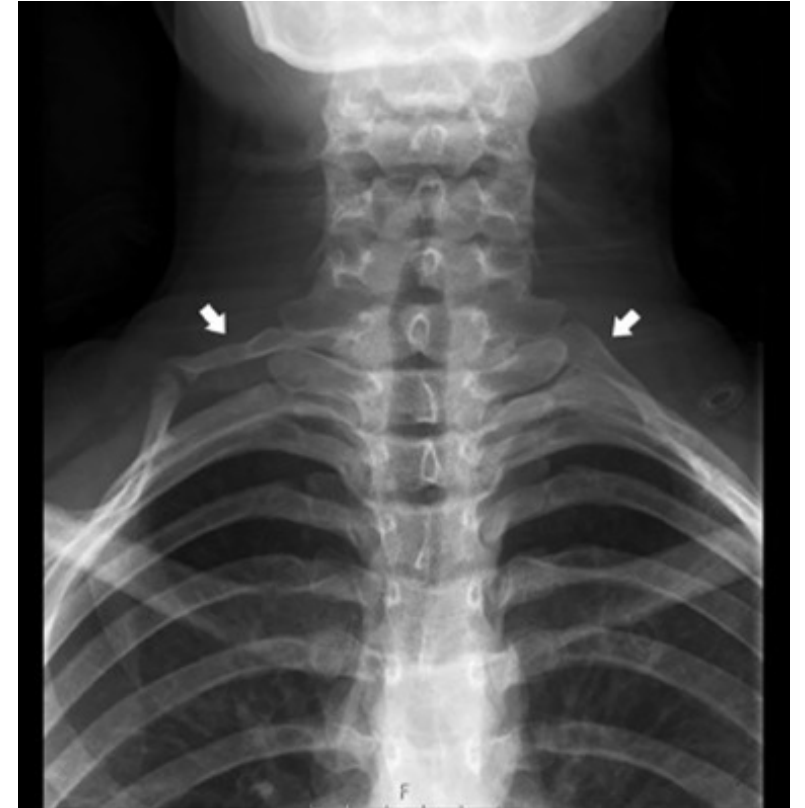- A. Entrapment of the posterior tibial nerve
- B. Morton neuroma
- C. Stress fracture
- D. Inflammation of the plantar aponeurosis

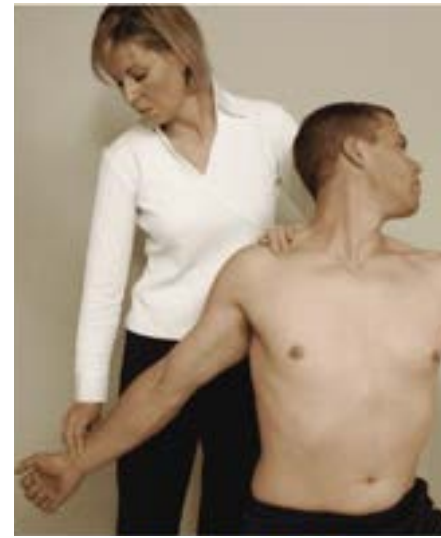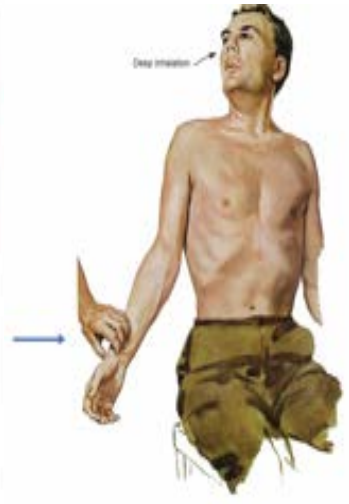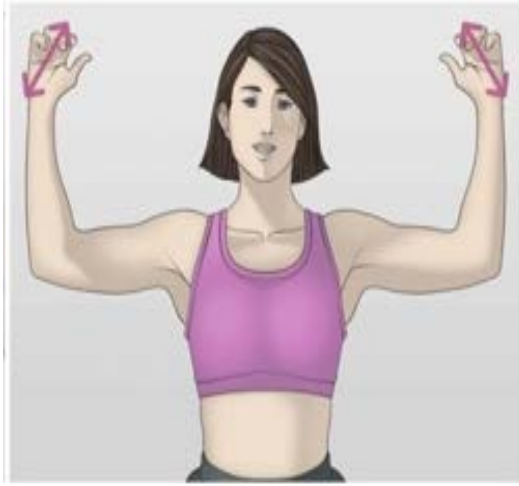34. A 35-year-old female came with persistent back ache, not responding to conservative treatment. She has a history of heavy weight lifting 4 months back with progressively increasing pain that worsens on walking and starts radiating down her legs within 100m range of walking, she however feels no pain on climbing up the stairs. Most probable diagnosis is?

- A. Vertebral osteoporotic compression fracture
- B. PIVD
- C. Lumbar canal stenosis
- D. PAD

35. A 45-year-old patient with suspected thoracic outlet syndrome is being examined. Hyperabduction of the arm on the affected side causes a reduction in the radial artery pulsation. X-ray is shown. What is this test known as?

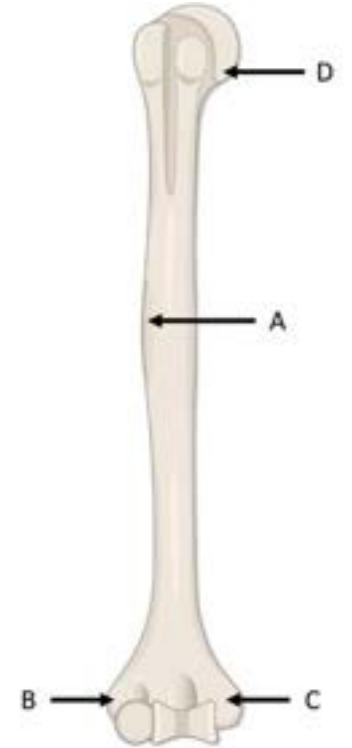
- A. Adson's test
- B. Halstead's maneuver
- C. Roos's test
- D. Wright's test





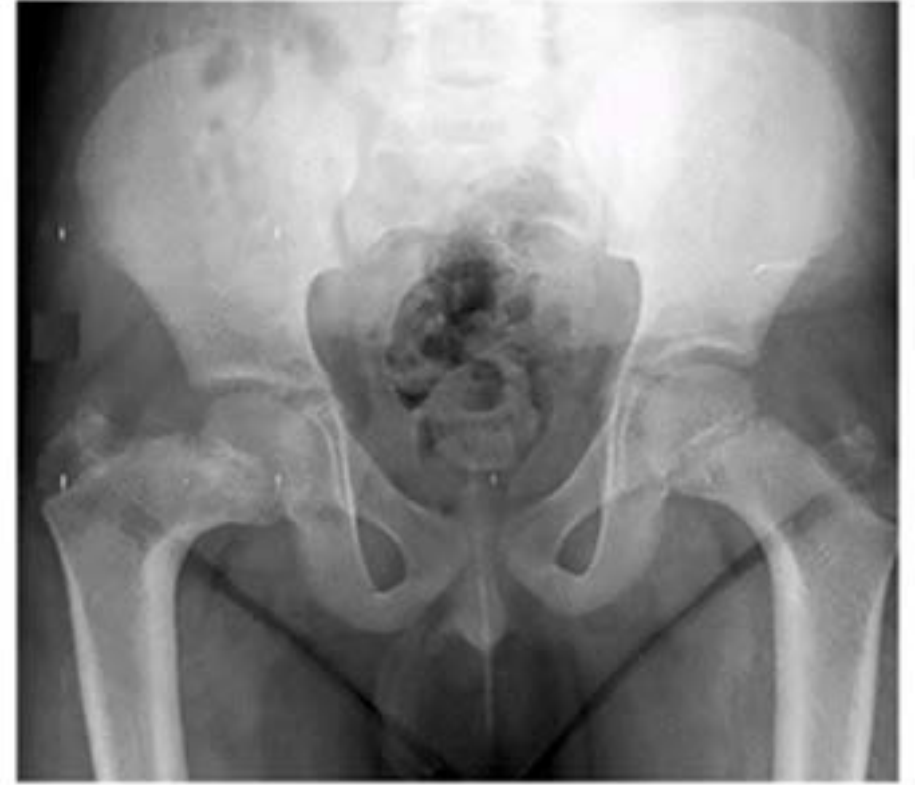36. A young man, aged 25, arrived with complaints of difficulty in gripping a piece of paper between his fingers. Where is the probable location of the injury?

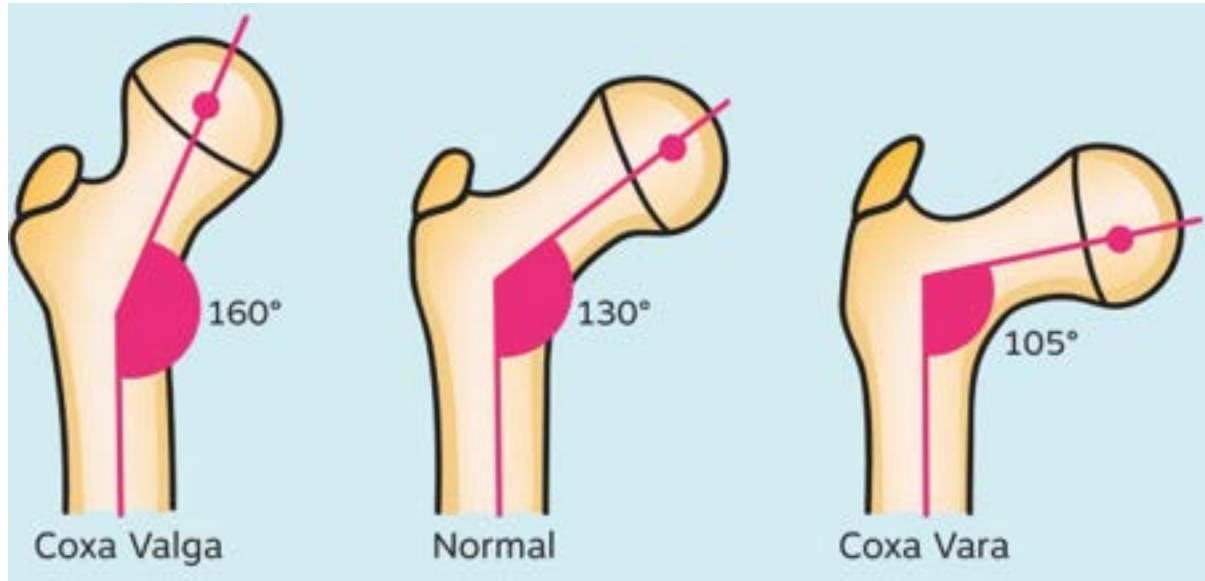
- A. A
- B. B
- C. C
- D. D



37. What is the likely diagnosis of the image shown below?

- A. Coxa magna
- B. Coxa valga
- C. Coxa vara
- D. Coxa sultans





38. Identify the correct statements with respect to CTEV.

1. 50% cases are bilateral with male predominance

2. Forefoot is adducted and supinated

3. Ponsetti technique is preferred for correction

4. Adduction should be corrected first

A. 1, 2, 3, 4

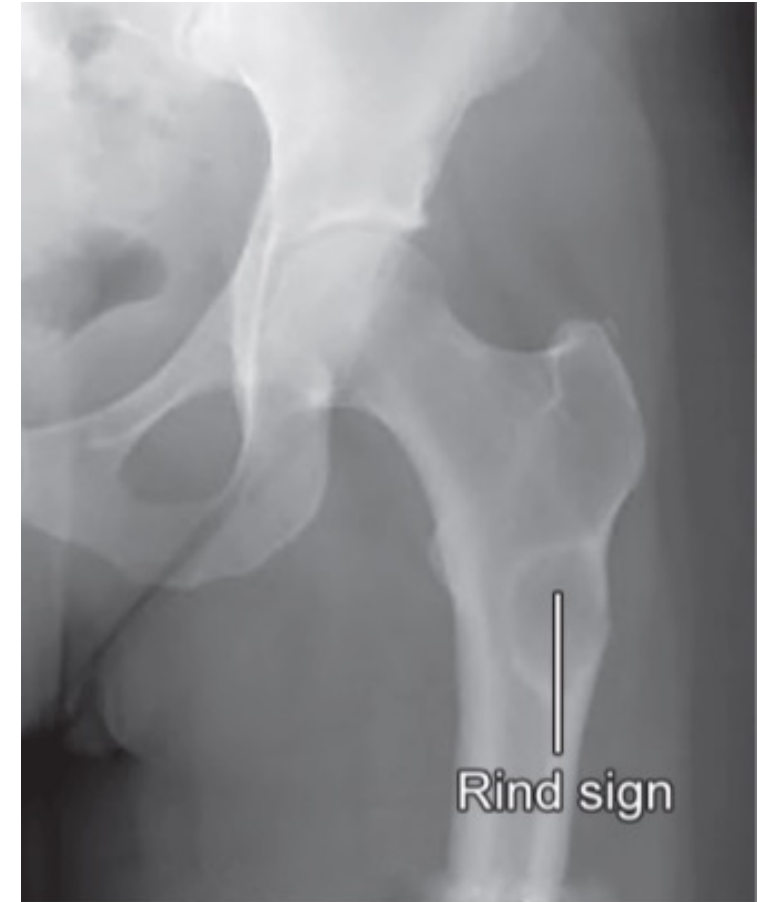B. 1, 2, 3

C. 2, 3

D. 1, 4

39. What is the likely diagnosis based in the given X-ray?

- A. ABC
- B. SBC
- C. Fibrous dysplasia
- D. Enchondroma

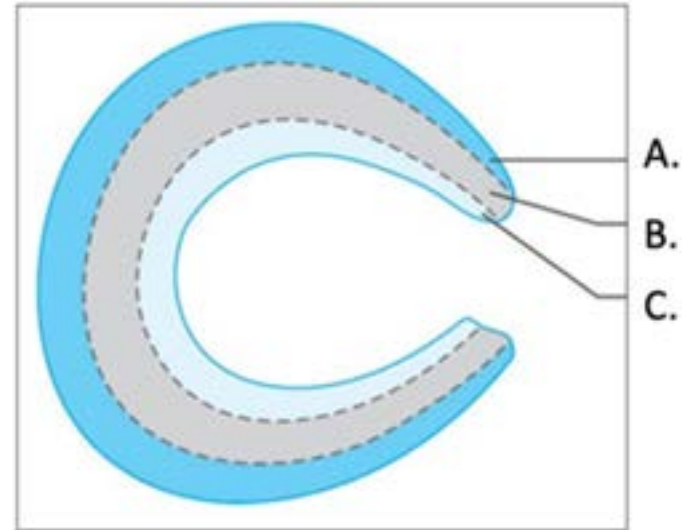


40. Which of the following is incorrect about nutritional Rickets?

- A. Normal Serum Calcium
- B. High Parathyroid hormone
- C. Low Serum Phosphorus
- D. High Urine Calcium to Creatinine Ratio

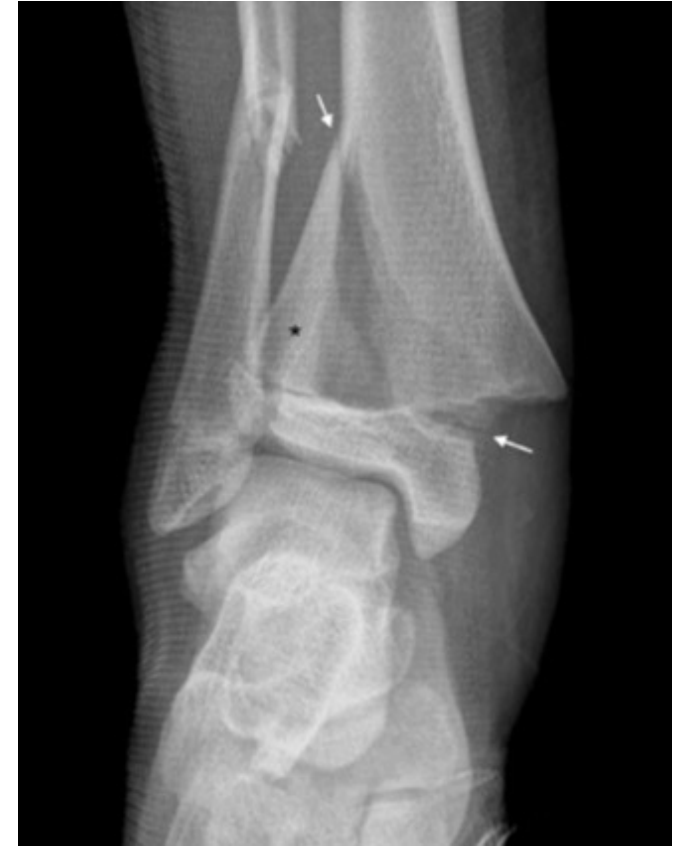41. Resection is performed for tears in which of the following locations?

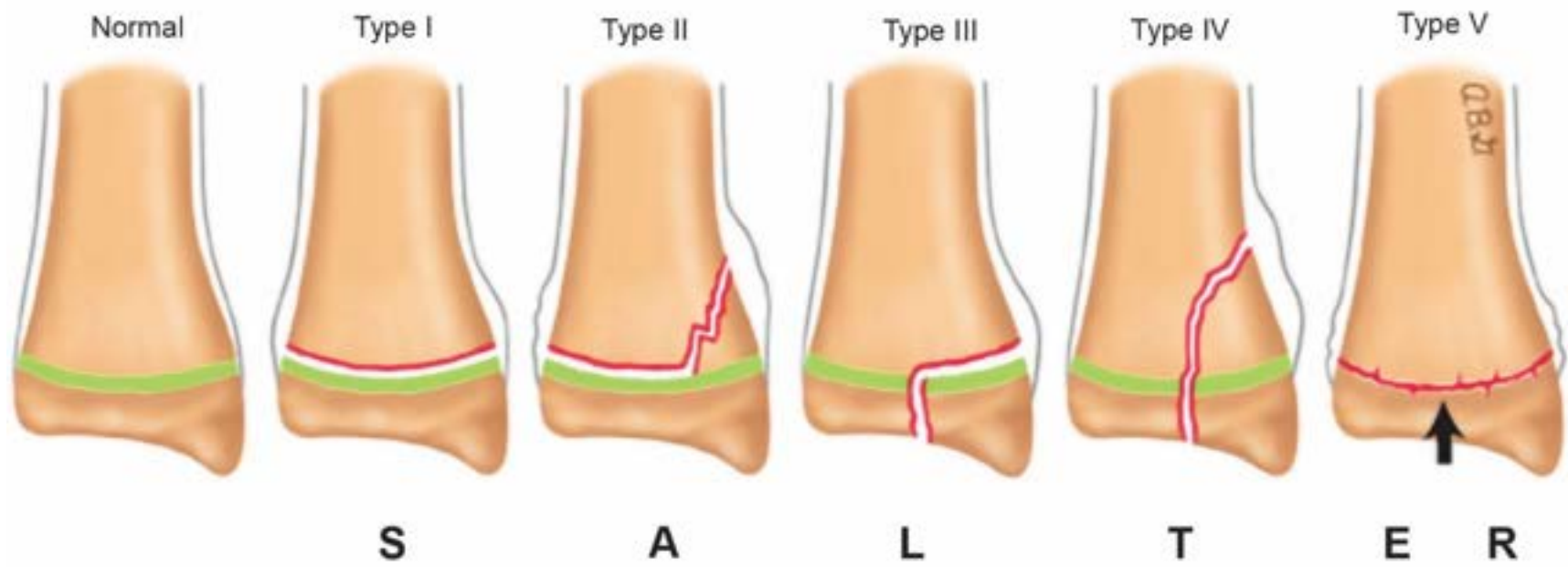
- A. A
- B. B
- C. C
- D. Depends on morphology rather than location



42. Identify the type of Salter-Harris injury

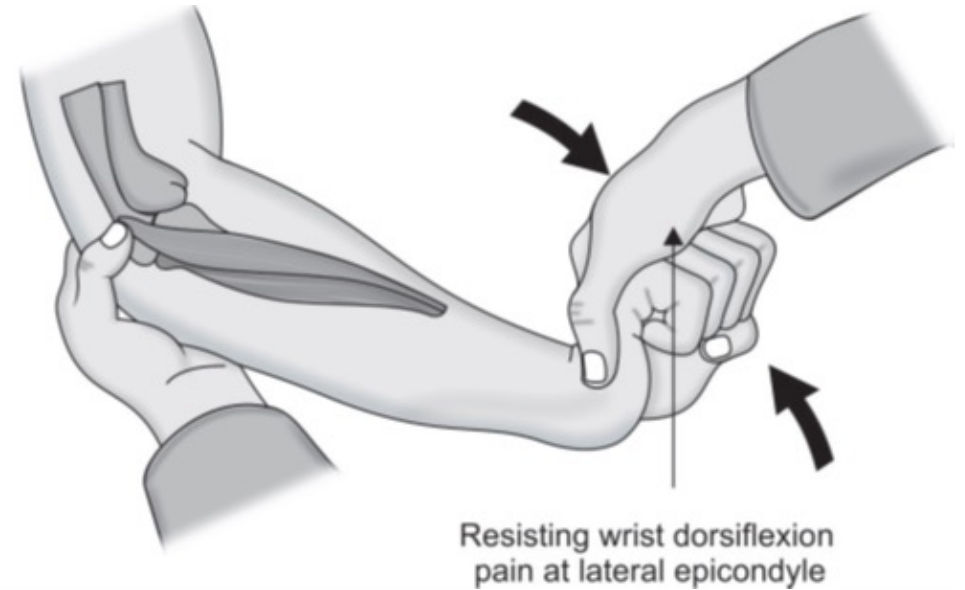
- A. Type 1
- B. Type 2
- C. Type 3
- D. Type 4





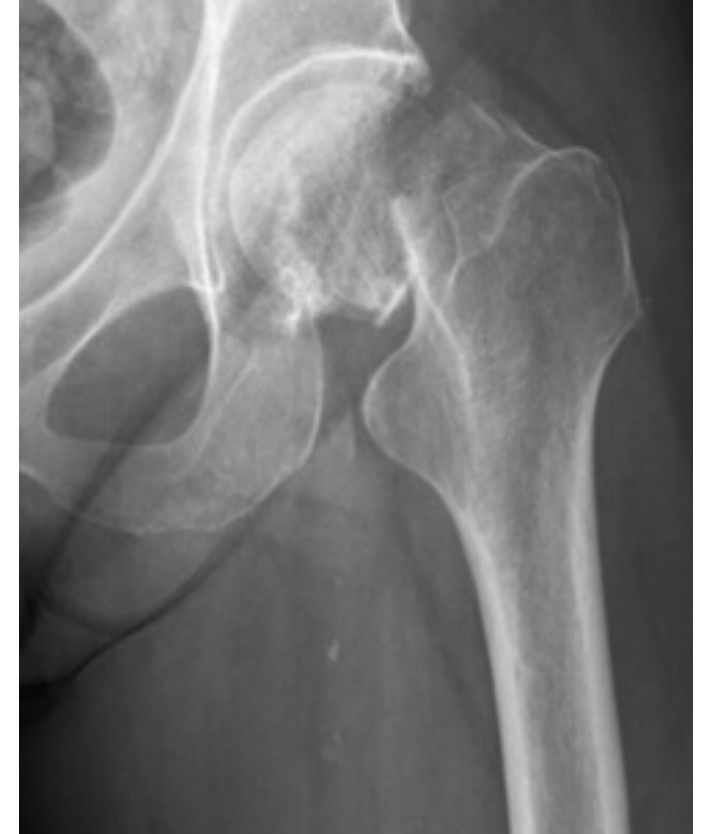43. The following test is useful for a diagnosis of?

- A. Golfer's elbow
- B. Carpal tunnel syndrome
- C. DeQuervian tenosynovitis
- D. Tennis elbow



44. A 45-year-old woman was taken to a trauma centre after suffering an accident. An X-ray of her pelvis was taken. In this instance, what is the management?

- A. Hemiarthroplasty
- B. Augmentation osteotomy
- C. Closed Reduction + Internal fixation
- D. Open Reduction + internal fixation

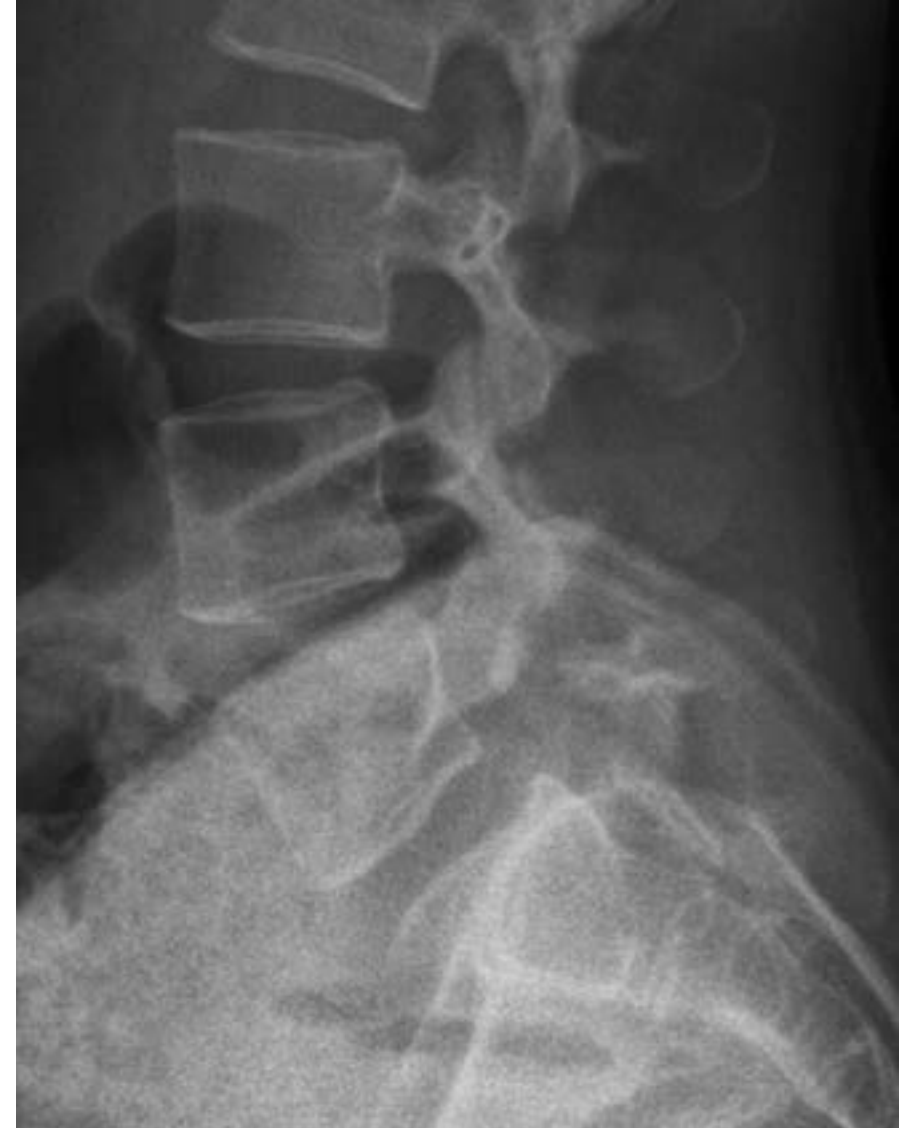

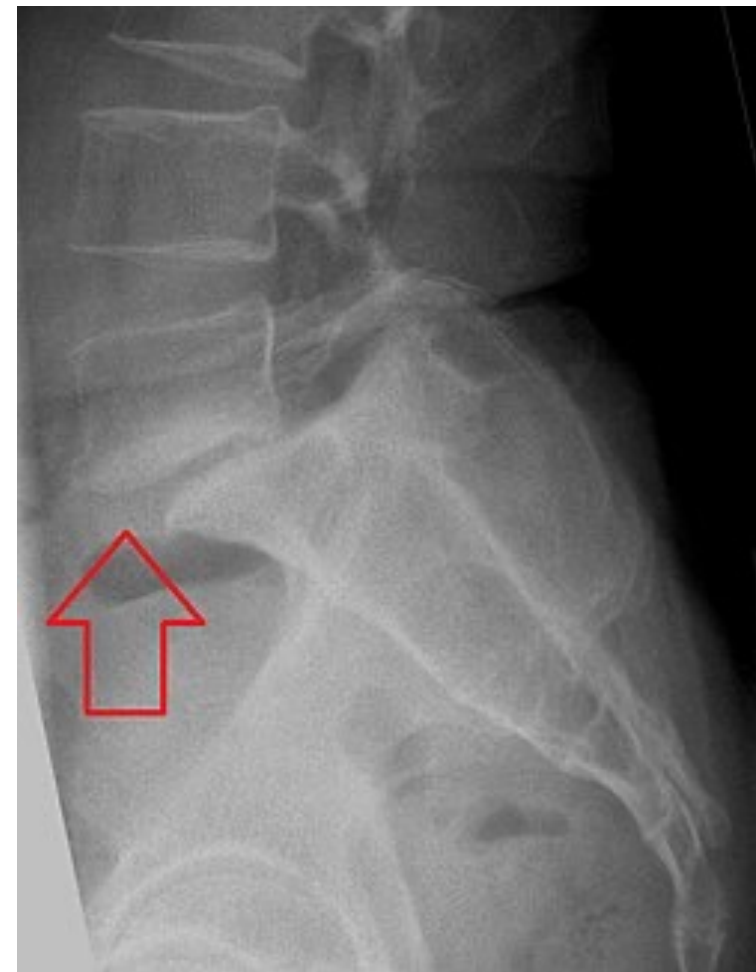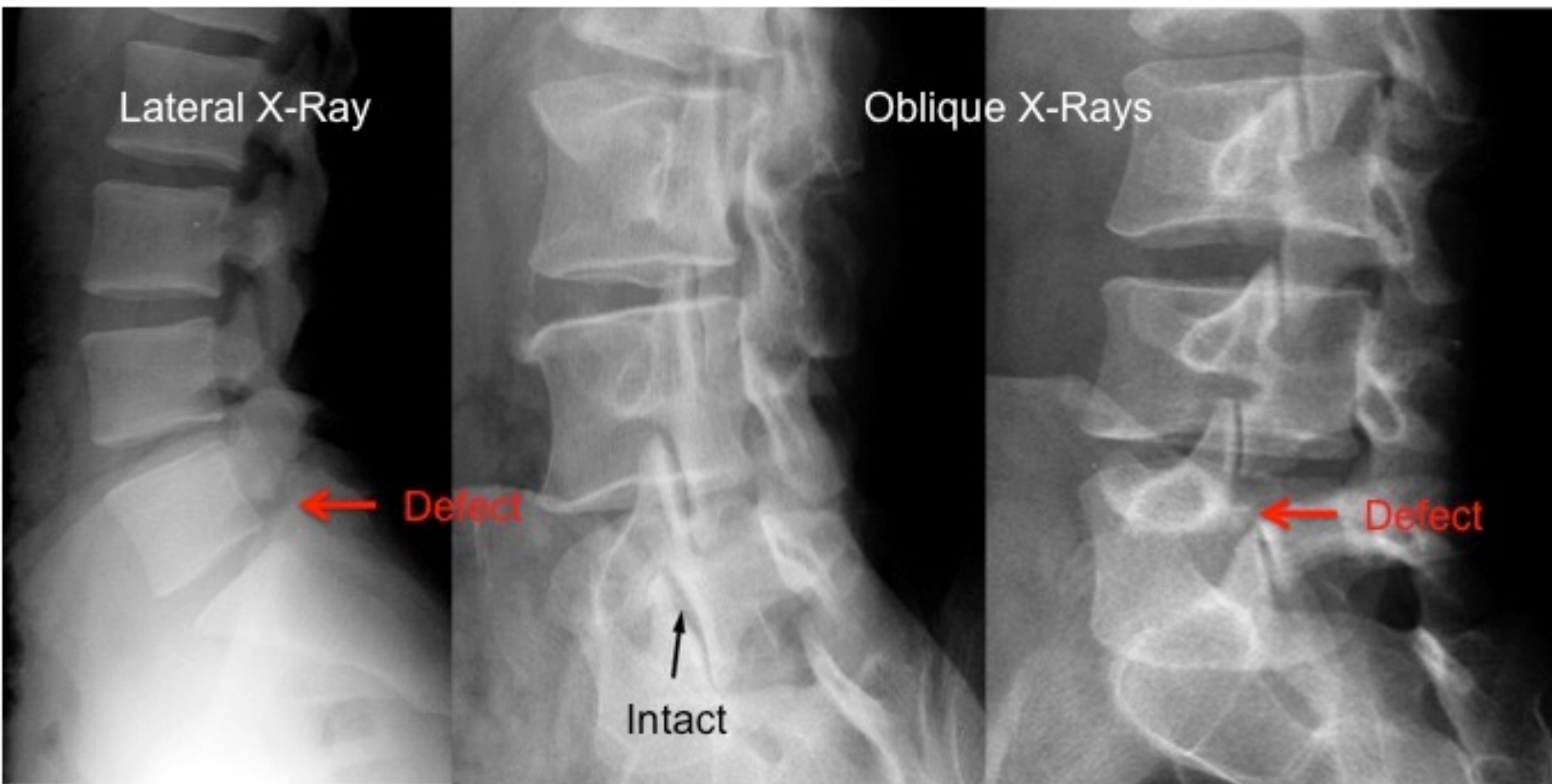
45. Identify the correct order of layers incised while performing a fasciotomy for compartment syndrome?

- A. Skin and Subcutaneous tissue
- B. Skin, Subcutaneous tissue, Superficial fascia
- C. Skin, Subcutaneous tissue, Superficial fascia and Deep fascia
- D. Skin, Subcutaneous tissue, Superficial fascia, Deep fascia and a few muscular fibers

46. What is the diagnosis in the following radiograph?

- A. Chance fracture
- B. Spondylolisthesis
- C. Spondylolysis
- D. Ankylosing spondylitis





47. Identify the incorrect statements

- 1. Tom smith arthritis most commonly affects the femoral capital epiphysis.**
- 2. De Quervain's tenosynovitis is the inflammation of the tendons of abductor pollicis longus and extensor pollicis brevis.**
- 3. Non-articular pain occurs only during passive movements.**
- 4. Singh's Index is used for TB grading.**

A. 1, 2, 3, 4

B. 3, 4

C. 1, 3

D. 2, 3, 4

Articular

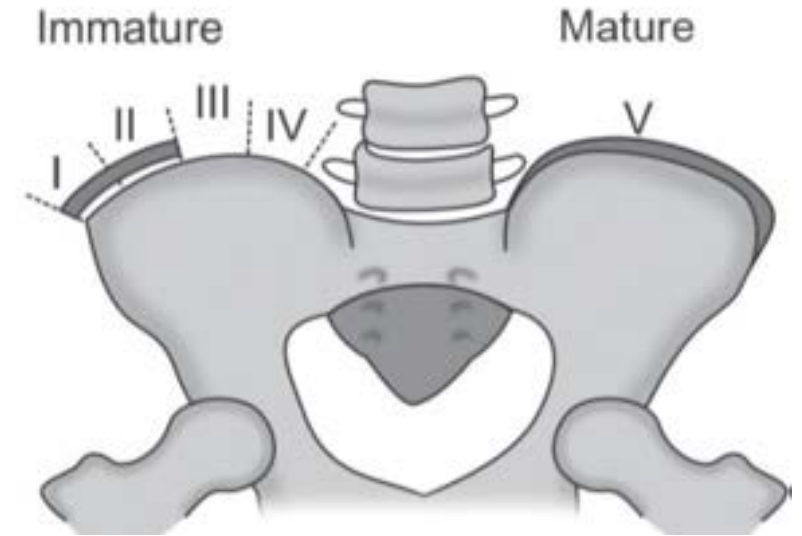
- Deep or diffuse pain– both active and passive
- Swelling of joint, Crepitation, Joint instability, Locking of joint, Deformity

Non-Articular

- Localised pain
- Painful active movements but not on passive**

48. The index shown in the image below is useful for planning management of which condition?

- A. Scoliosis
- B. DDH
- C. Ankylosing spondylitis
- D. AVN



49. An orthopedic surgeon plans to treat a Colle's fracture. What are the steps involved in applying a cast for the same?

I. Palmar flexion

II. Traction

III. Ulnar deviation

IV. Pronation

A. I, II, III, IV

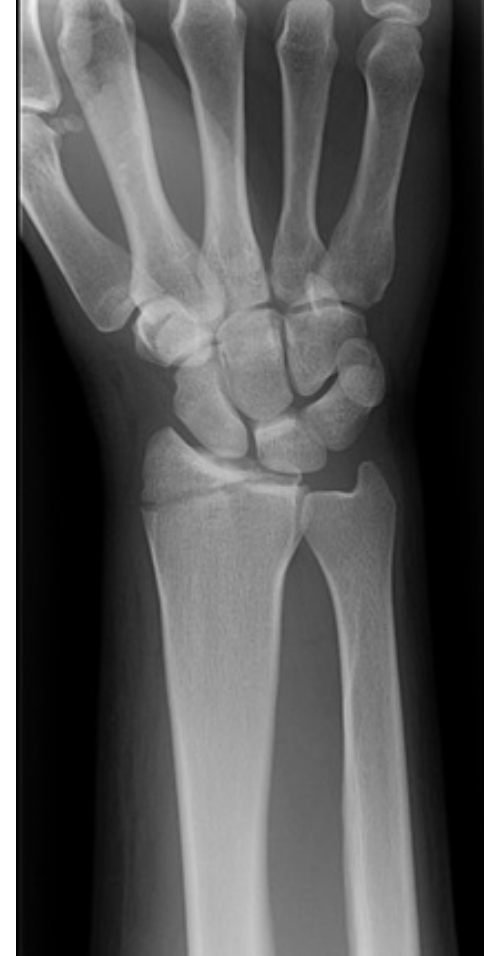B. I, II, IV, III

C. II, I, III, IV

D. II, IV, I, III

50. A 40-year-old man presents with wrist pain after a fall on an outstretched hand. The X-ray is shown below. What is the most likely diagnosis?

- A. Colles' fracture
- B. Smith's fracture
- C. Volar Barton's fracture
- D. Chauffer fracture



51. A young female patient complains of low back pain radiating to the right hip, back of the thigh, leg, and ankle after an intense workout of lifting some heavy weights. MRI shows the following finding. Which function will be weak here?

- A. Hip flexion
- B. Ankle dorsiflexion
- C. EHL
- D. Ankle plantar flexion

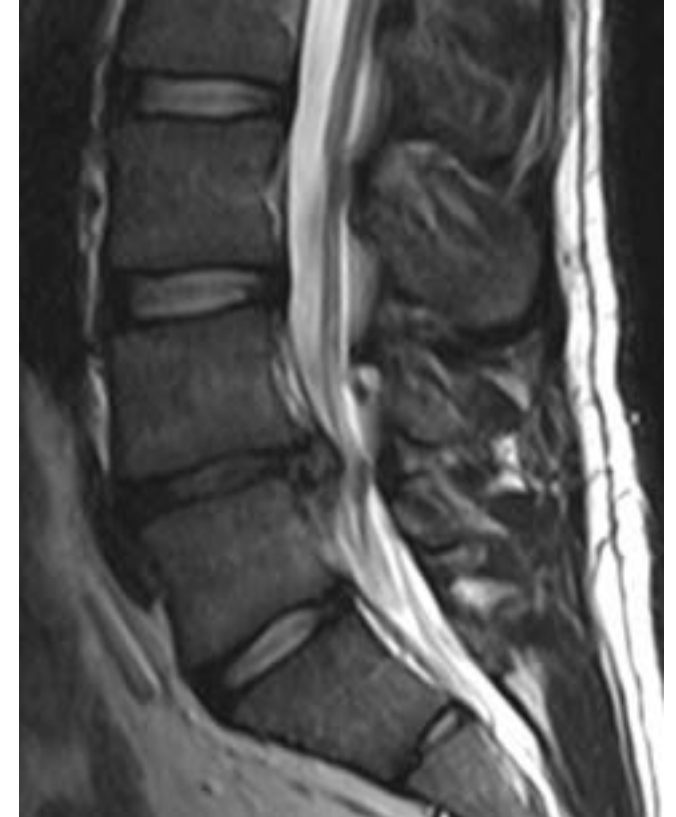

TABLE 37.2 Neurological evaluation of the upper limb.

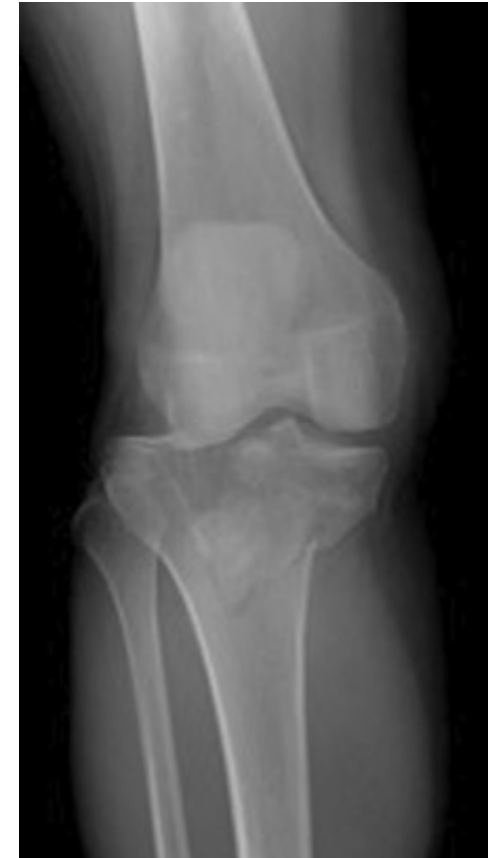| Neurological level | Motor | Sensation | Reflexes |
|--------------------|---------------------|-----------------|------------------------|
| C5 | Deltoid | Lateral arm | Biceps (C5/6) |
| C6 | Wrist extensors | Lateral forearm | Brachioradialis (C5/6) |
| C7 | Triceps | Middle finger | Triceps (C7/8) |
| C8 | Long finger flexors | Medial forearm | No reflex |
| T1 | Interosseus muscles | Medial arm | No reflex |

TABLE 37.3 Neurological evaluation of the lower limb.

| Neurological level | Motor | Sensation | Reflexes |
|--------------------|--------------------------|-----------------------------|-----------------|
| L2 | Hip flexion | Anterior thigh, groin | No reflex |
| L3 | Knee extension | Anterior and lateral thigh | Patellar (L3/4) |
| L4 | Ankle dorsiflexion | Medial leg and foot | Patellar (L3/4) |
| L5 | Extensor hallucis longus | Lateral leg and foot | No reflex |
| S1 | Ankle plantarflexion | Lateral foot and little toe | Achilles (S1/2) |

52. What is the correct classification for the following?

- A. Neer classification grade 4
- B. Ideberg classification grade 4
- C. Sander classification grade 3
- D. Schatzker classification grade 4

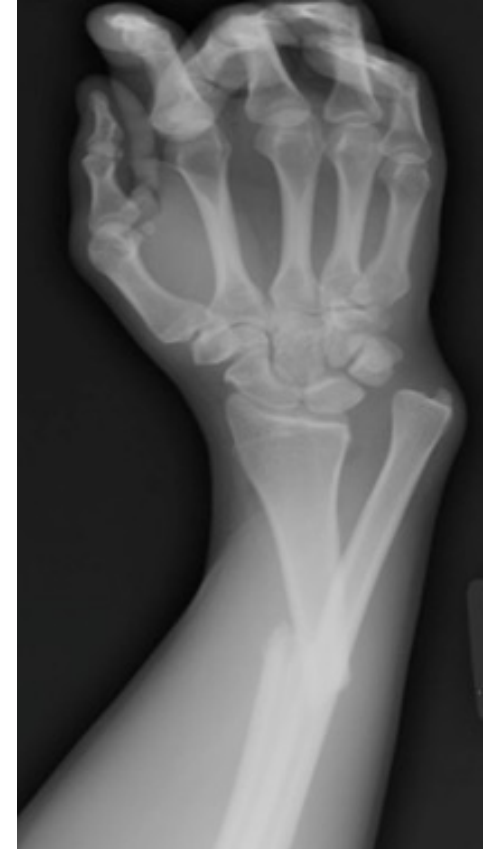

53. In a patient with Colles fracture, rupture of which tendon is most commonly seen?

- A. Extensor pollicis longus
- B. Extensor carpi ulnaris
- C. Abductor pollicis longus
- D. Extensor pollicis brevis

54. What is the most appropriate treatment for the following fracture?

- A. External fixation with Ilizarov frame
- B. Closed reduction with below-elbow cast
- C. Internal fixation using compression plate
- D. Closed reduction with above-elbow cast

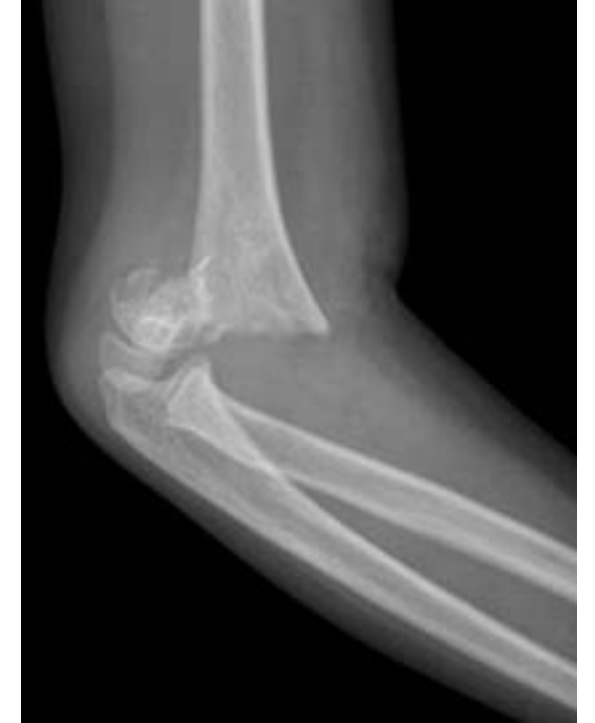

Fractures of necessity

- Lateral condyle fracture humerus
- Displaced fracture of olecranon and patella
- Fracture neck of femur
- Galeazzi fracture-dislocation
- Monteggia fracture in adults
- Intra-articular fractures

55. A 4-year-old presents with a pink but pulseless arm following an injury. Xray is shown below. What is the best next step?

- A. Observation
- B. Vascular repair
- C. Fasciotomy
- D. Reduction and pinning



56. A 25-year-old mason presents with left hip flexed as shown below after a fall. Which statement is false about the likely diagnosis?

- A. Femoral head appears smaller than the other side on X-ray
- B. Femoral vessels may be injured
- C. Stimson's method can be used to reduce it
- D. Femoral head palpable in the groin



57. A 45 year old male patient sustained a tibial fracture was managed conservatively with a plaster cast. A few days later, severe pain was elicited on passive stretching. What is the indication of fasciotomy in this patient?

- A. Differential pressure less than 30 mmHg
- B. Differential pressure more than 30 mmHg
- C. Compartment pressure less than 30mm Hg
- D. Diastolic blood pressure more than 100mm Hg

58. A 45-year-old man is brought to the emergency department following a motor vehicle collision. He reports right hip pain and numbness along the right thigh. Physical examination shows decreased sensation to light touch over a small area of the medial thigh. X-rays of the pelvis show a displaced pelvic ring fracture. Further evaluation of this patient is most likely to show which of the following findings?

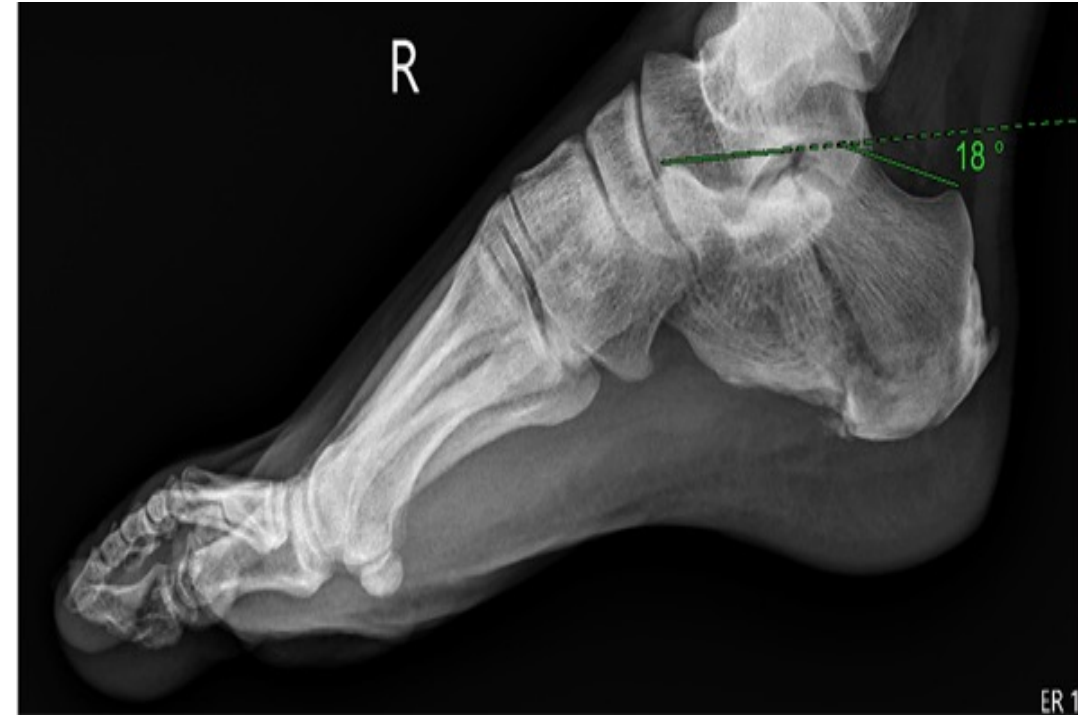- A. Sensory deficit of the dorsal foot
- B. Impaired hip extension
- C. Impaired dorsiflexion of the foot
- D. Impaired adduction of hip

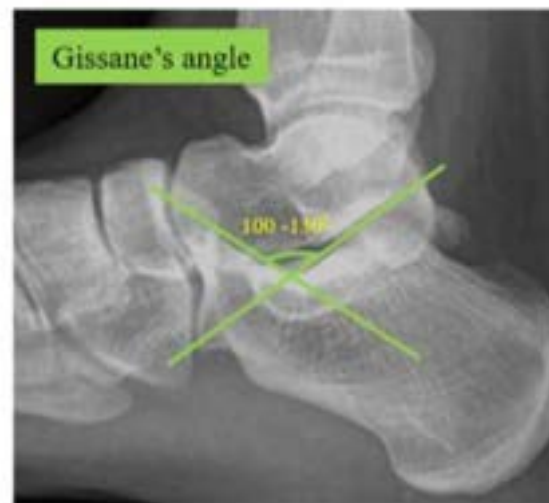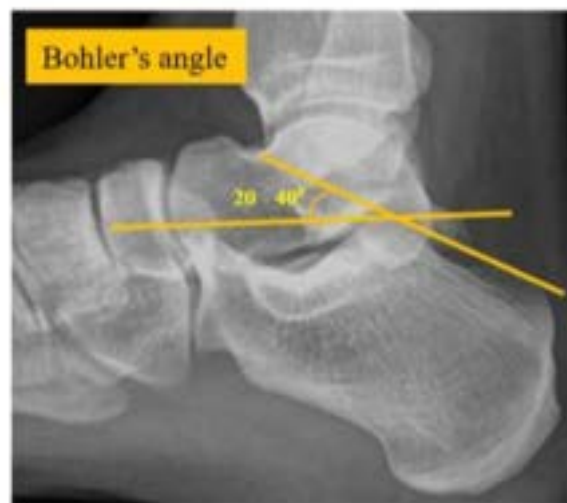59. A 41-year-old woman comes to the doctor because of gradually progressive weakness in her right hand over the past few weeks. She goes to the gym to lift weights 5 times a week. With the dorsum of the right hand on a flat surface, the patient is unable to move her thumb to touch a pen held 2 cm above the interphalangeal joint of the thumb. An MRI of the right arm shows compression of a nerve that passes through the pronator teres muscle. Based on the examination findings, loss of innervation of which of the following muscles is most likely in this patient?

- A. Adductor pollicis
- B. Abductor pollicis brevis
- C. Extensor pollicis brevis
- D. Abductor pollicis longus

60. A patient presents with left heel pain following a fall from a ladder. A lateral radiograph of the left foot is shown. What is the most likely diagnosis?

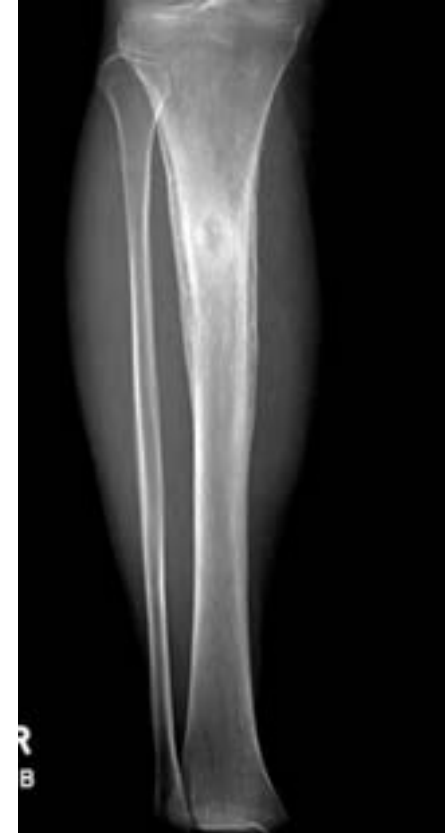- A. Calcaneal fracture with reduced Bohler angle
- B. Calcaneal fracture with increased Bohler angle
- C. Calcaneal fracture with reduced Gissane angle
- D. Calcaneal fracture with increased Gissane angle





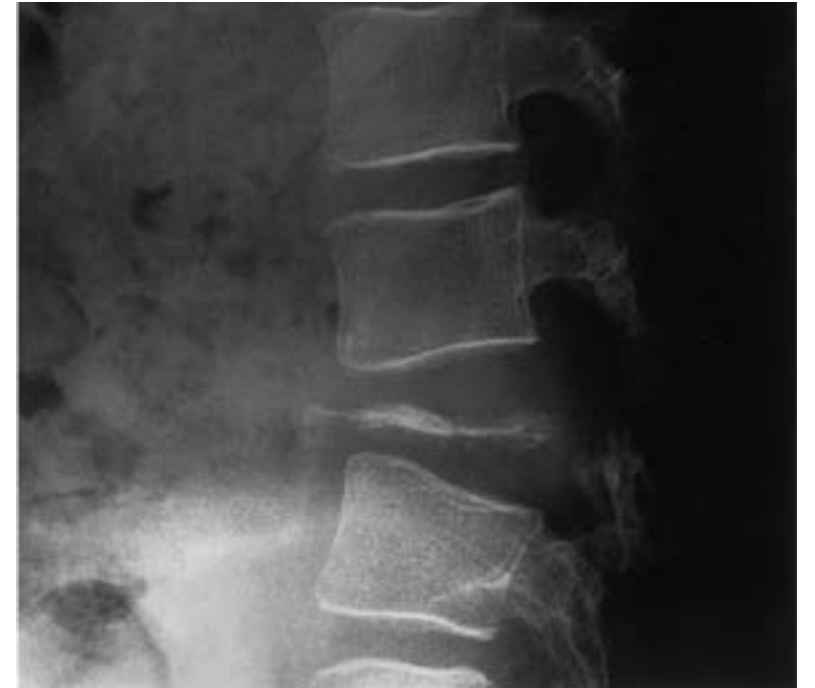
61. A 15-year-old male with pain and swelling gradually increasing over 4 months at the upper end of tibia. What is the likely diagnosis?

- A. Osteoclastoma
- B. Ewing sarcoma
- C. Brodie abscess
- D. Osteosarcoma



62. 6-year-old boy is brought to the OPD for evaluation of back pain. The pain has been constant for the last 2 weeks and keeps the patient from playing with his friends. He wakes up several times nightly to void and has had episodes of incontinence as the leg pain prevents him from walking to the bathroom. Which of the following is the most likely diagnosis in this patient?

- A. Langerhans cell histiocytosis
- B. Ewing sarcoma
- C. Mazabraud syndrome
- D. McCune Albright syndrome



63. 6-year-old girl is brought to the clinic for evaluation of knee pain. The patient first had soreness in her right knee 4 days ago, after her first gymnastics class. Her mother gave her PCM and massaged her knee, but this did not help. The patient also developed a limp over the past 2 days. She has no chronic medical conditions and does not take daily medications. Height is at the 50th percentile and weight is at the 90th percentile. Temperature is 37.9 C (100.2 F). When walking, she limits weight-bearing on her right side. When supine, the right hip is held flexed with the knee pointed laterally. There is limited internal rotation and extension of the right hip. The right knee has full range of motion and there is no tenderness on palpation around the knee. Laboratory evaluation shows leukocyte count of 11,500/mm and C-reactive protein of 8 mg/L (normal: <10). Ultrasound of the hips shows small, bilateral effusions. Which of the following is the most likely diagnosis in this patient?

- A. Juvenile idiopathic arthritis
- B. Perthes disease
- C. Slipped capital femoral epiphysis
- D. Transient synovitis

64. All of the following are susceptible to AVN except:

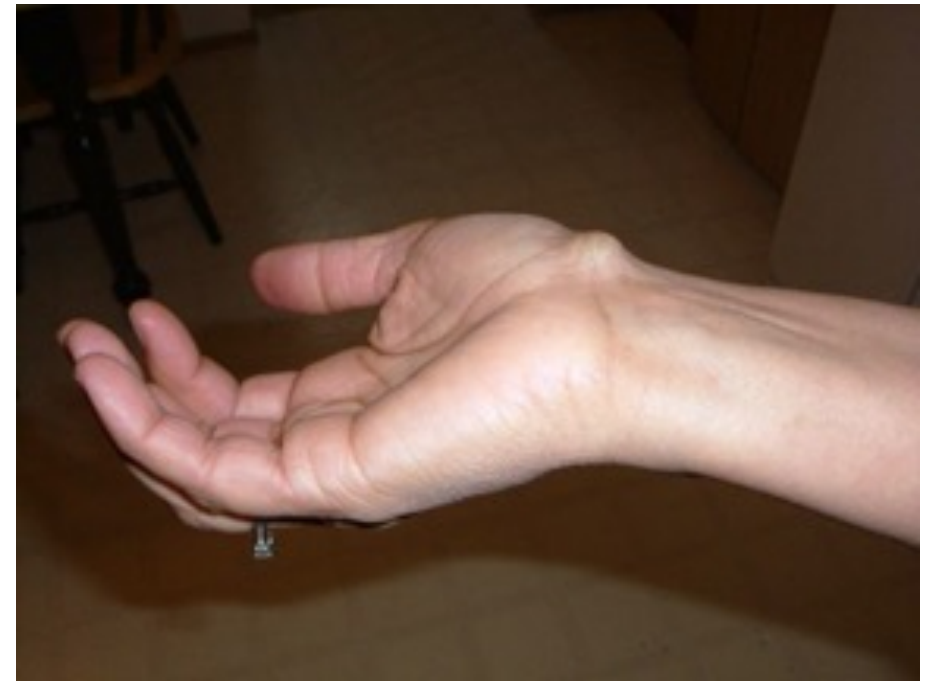- A. Proximal pole of scaphoid
- B. Neck of talus
- C. Head of femur
- D. Head of humerus

65. 10-year-old girl with Down syndrome is brought to the clinic due to behavioural changes. Over the past month, she has stopped running, tripped frequently while walking, and accidentally knocked toys over more often than normal. The patient was toilet-trained at age 4, but recently she began having frequent urinary accidents while playing and has started wearing a diaper again. Physical examination shows an ataxic gait. Bilateral ankle deep tendon reflexes are hyperreflexic. When the soles of the feet are firmly stroked the big toes move upward and the other toes fan out. Urinalysis is normal. Which of the following is the most likely cause of this patient's presentation?

- A. Early onset Alzheimer-disease
- B. Atlantoaxial instability
- C. Hypothyroidism
- D. Spinal cord infarction

66. A 42-year-old woman comes to the office for evaluation of a mass at her right wrist. The patient first noticed swelling in her wrist a few months ago after spending a week knitting blankets for her family. Medical conditions include hyperlipidemia and rheumatoid arthritis. The mass is firm, mobile, and nontender to palpation, and it transilluminates on penlight examination. Which of the following is the most likely diagnosis in this patient?

- A. Epidermoid cyst
- B. Ganglion cyst
- C. Lipoma
- D. Rheumatoid nodule

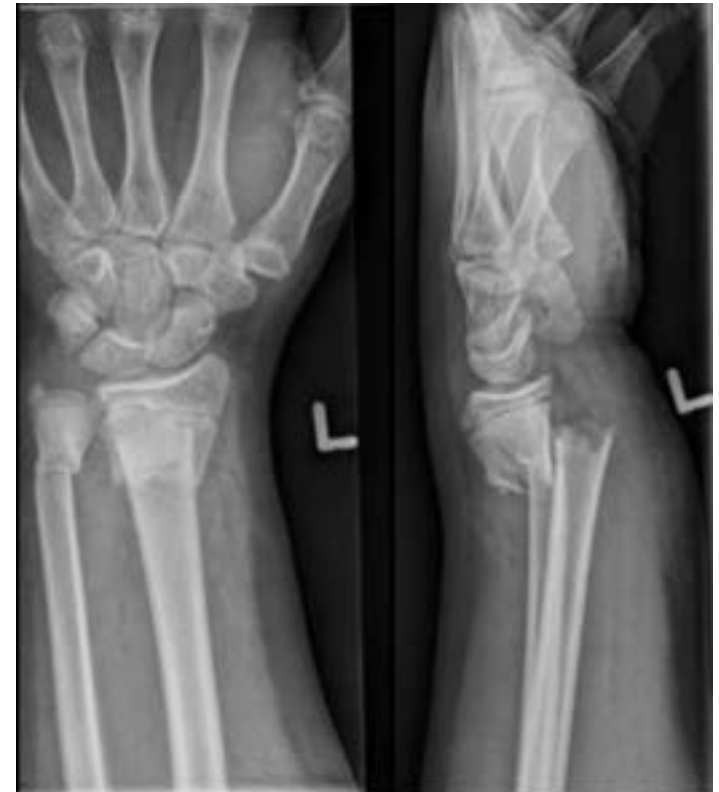

67. A 40-year-old man comes to the emergency department due to worsening right lower abdominal pain that radiates to the right groin area. Two weeks ago, he was treated for furunculosis of the right thigh. The patient has a history of type 1 diabetes mellitus and takes insulin. Abdominal examination shows tenderness on deep palpation in the right lower quadrant without rebound or guarding. No masses are palpated. Bowel sounds are present. Extension of the right hip increases pain, and flexion decreases pain. Which of the following is the likely diagnosis?

- A. Acute appendicitis
- B. Psoas abscess
- C. Small bowel obstruction
- D. Acute pancreatitis

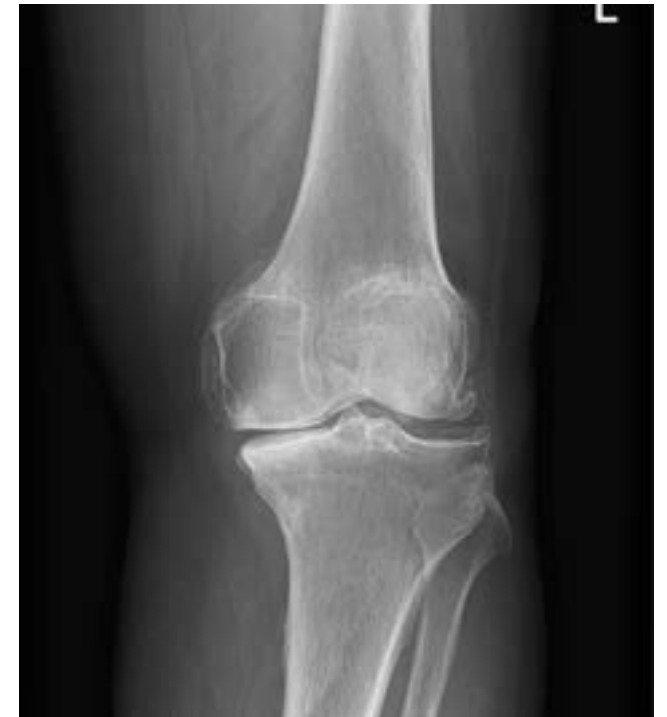68. A 45-year-old man comes to the emergency department due to left wrist pain after a fall. The patient was walking in his house when he tripped over a rug and landed on his outstretched hand. Medical history is notable for celiac disease, hypertension, and hypothyroidism for which he takes appropriate daily medications. X-ray of the left wrist is shown below. Which of the following is the most significant risk factor for bone fracture in this patient?

- A. Age
- B. Celiac disease
- C. Hypertension
- D. Hypothyroidism



69. 61-year-old man comes to the OPD due to chronic left knee pain. The pain is worse when he first gets out of bed in the morning and is associated with mild stiffness. On examination, the left knee has a small effusion and mild pain over the medial and lateral joint lines. There is no clicking or locking of the knee, but crepitus is present with range of motion. The patient is able to bear weight without pain and the joint is stable to varus and valgus stress. X-ray of the knee is shown in the image below: Which of the following is the most appropriate initial treatment for this patient's knee pain?

- A. Methotrexate
- B. Corticosteroid injection of the knee
- C. Knee replacement surgery
- D. Quadriceps strengthening exercises

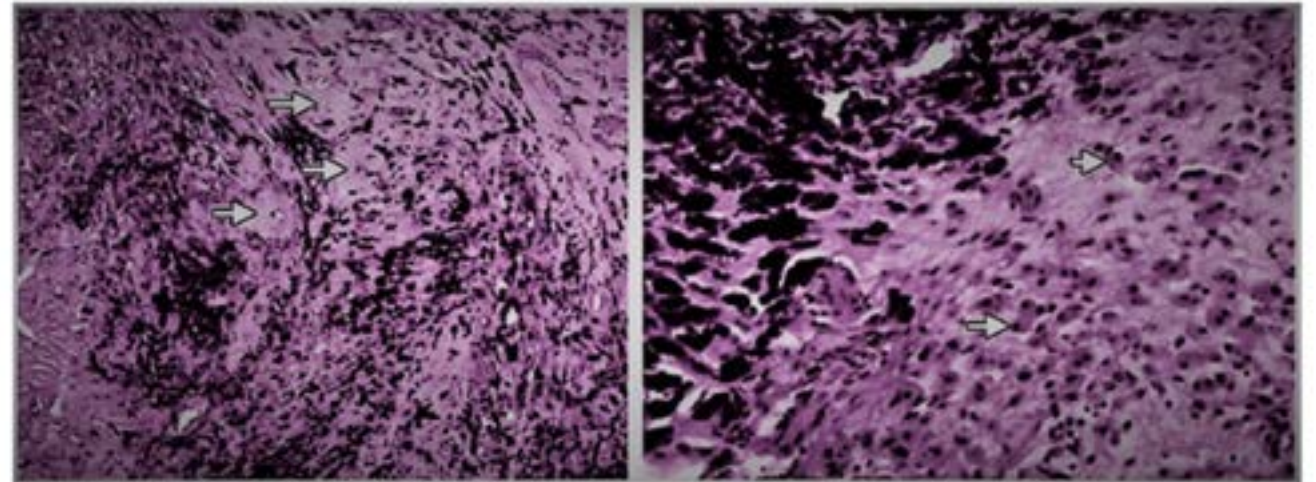


70. 26-year-old man with a history of seizure disorder and medication nonadherence is hospitalized after a generalized tonic-clonic seizure. A witness reports that the patient lost consciousness and fell to his right side; the seizure lasted about 2 minutes. Evaluation in the emergency department reveals a low serum level of his prescribed antiepileptic drug, levetiracetam, and a displaced right femur fracture. Levetiracetam is restarted and the patient undergoes intramedullary nailing of the fracture with no intraoperative complications. The next day the patient is noted to be confused. Temperature is 37.2 C (99 F), blood pressure is 142/86 mm Hg, pulse is 102/min, and respirations are 28/min. Oxygen saturation is 90% while breathing room air. On physical examination, the patient is disoriented but has no focal weakness or sensory loss. There are no skin rashes or hematoma at the surgical site. CT pulmonary angiography shows bilateral scattered ground-glass opacities but no filling defects within the pulmonary vasculature. Which of the following is the most likely cause of this patient's current condition?

- A. Aspiration pneumonitis
- B. Cardiogenic pulmonary edema
- C. Drug-induced hypersensitivity reaction
- D. Fat embolism

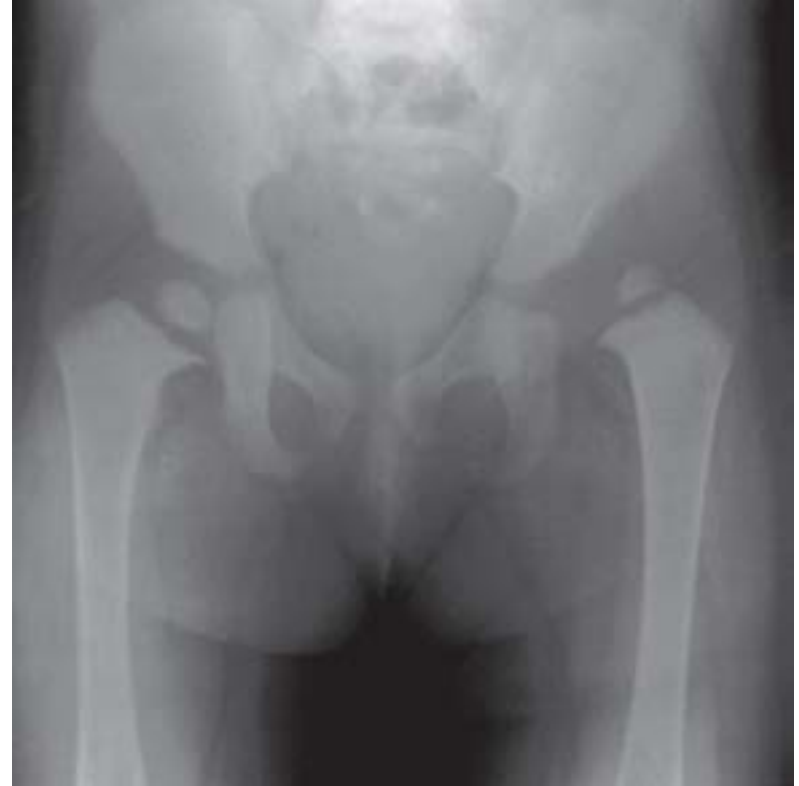71. A 60 year old female underwent hip replacement. After 1 year she developed fever and pain in the joint. Radiograph revealed loosening of prosthesis. The implant had to be removed. The histological image of the tissue adjoining the implant is show below. What is the diagnosis?

- A. Metallosis
- B. Melanoma
- C. Ochronosis
- D. Rosai Dorfmann Syndrome



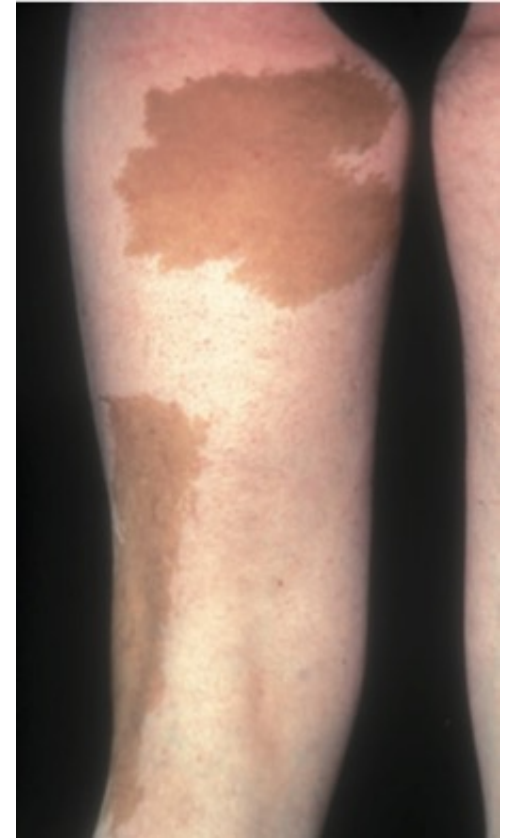
72. The following pelvic X-ray was seen in a patient. All the following signs will be present except:

- A. Ortolani sign
- B. Barlow sign
- C. Narath sign
- D. Gaenslen sign



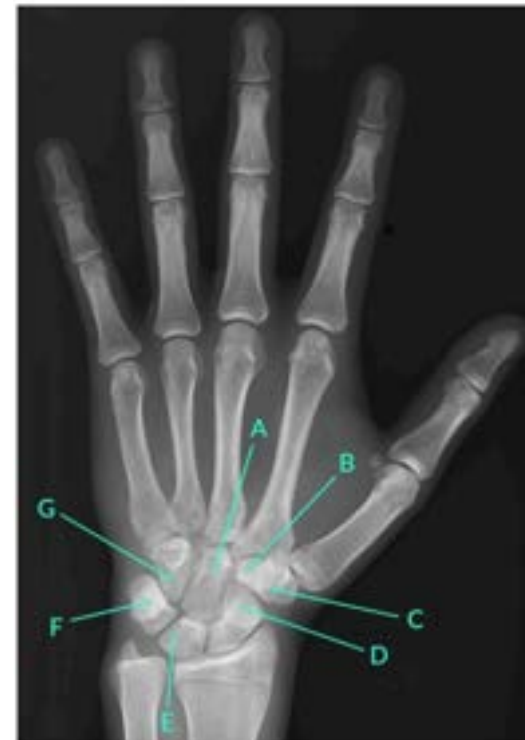73. A 6-year-old girl is evaluated for early-onset puberty and multiple bone lesions. On examination, she has café-au-lait spots as shown below. Hormonal tests confirm hyperfunction of multiple endocrine glands. What is the underlying genetic mutation in this condition?

- A. NF1 gene
- B. GNAQ gene mutation
- C. GNAS gene mutation
- D. FGFR3



74. A 19-year-old man comes to the physician because of episodic tingling and numbness in his right hand for the past 3 weeks. He says that he cannot hold a pen very well and that this is affecting his handwriting. Sensation to light touch is decreased over the right little finger and the medial palmar surface of the right hand. Radiologic evaluation in this patient is most likely to show a fracture in which of the following bones?

- A. A
- B. C
- C. D
- D. G

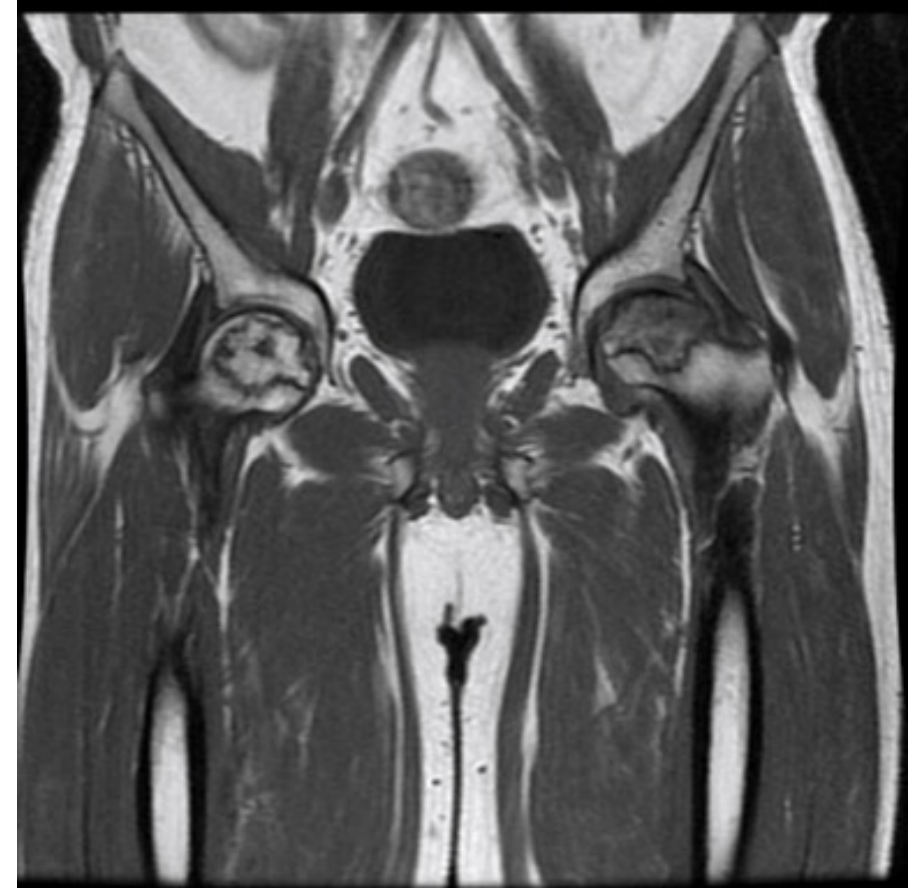


75. A previously healthy 2-year-old boy is brought to the emergency room by his mother because of persistent crying and refusal to move his right arm. The episode began 30 minutes ago after the mother lifted him up by the arms. He appears distressed and is inconsolable. On examination, his right arm is held close to his body in a flexed and pronated position. Which of the following is the most likely diagnosis?

- A. Proximal ulnar fracture
- B. Anterior shoulder dislocation
- C. Supracondylar fracture of the humerus
- D. Radial head subluxation

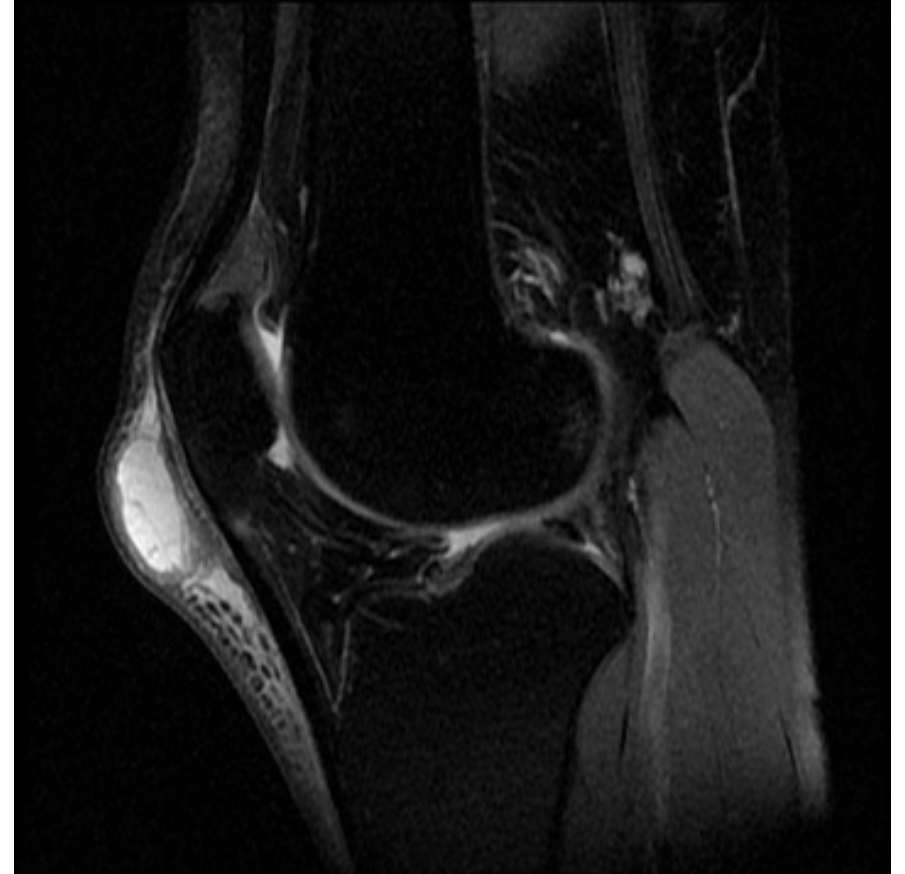
76. The following condition develops due to which vessel?

- A. Medial circumflex femoral artery
- B. Lateral circumflex femoral artery
- C. Obturator artery
- D. Profunda femoris artery



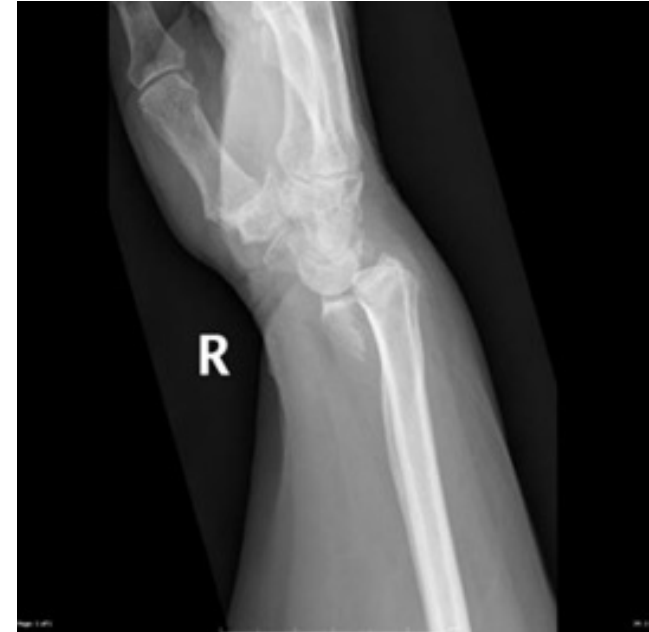77. A 42-year-old female complains of soft, fluctuating swelling in front of the knee. She reports discomfort and difficulty while moving her knee. MRI is shown below. What is the most probable diagnosis?

- A. Cleryman's knee
- B. Housemaid's knee
- C. Gout
- D. Pes anserinum bursitis



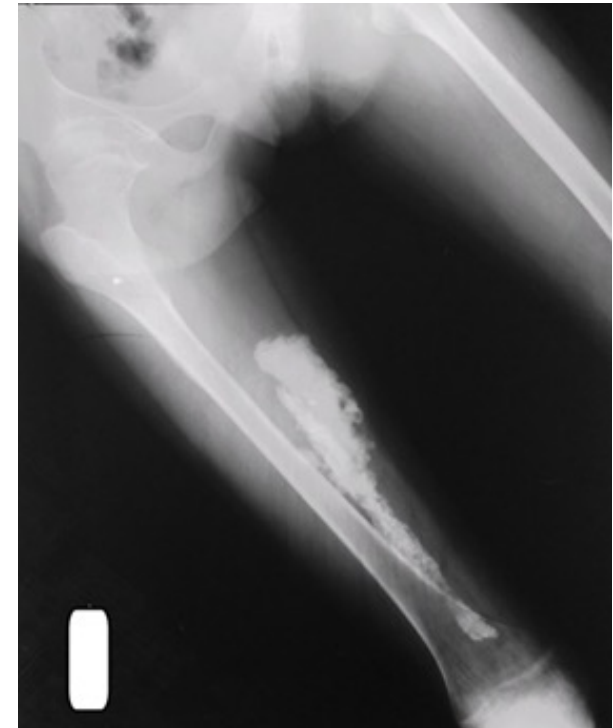78. A 40-year-old man presents with wrist pain after a fall on an outstretched hand. The X-ray is shown below. What is the most likely diagnosis?

- A. Colles' fracture
- B. Smith's fracture
- C. Volar Barton's fracture
- D. Scaphoid fracture



79. A 19-year-old male patient comes to the clinic for follow-up 3 weeks after a traumatic fracture in his right thigh. On examination, he was found to have a hard palpable mass near the fracture site. X-ray of the area shows the findings below. A histological section shows central fibrous tissue and mature bone at the periphery. Which of the following is true about this patient's diagnosis?

- A. Parosteal osteosarcoma
- B. Myositis ossificans
- C. Osteochondroma
- D. AV fistula



80. Identify the incorrect statement about Seddon classification of nerve injuries:

- A. No loss of nerve sheath continuity in Neurapraxia and axonotmesis
- B. Wallerian degeneration is not seen in neurapraxia
- C. Surgical intervention is always needed in neurotmesis
- D. Nerve regrowth happens at 3mm per day

Seddon classified nerve injuries into neurapraxia, axonotmesis and neurotmesis:

- Neurapraxia – no loss of nerve sheath continuity or peripheral Wallerian degeneration. If the pressure is removed from the nerve, recovery potential is good but may take months.
- Axonotmesis – nerve sheath remains intact, with internal nerve fibre damage and associated Wallerian degeneration. The neural tube (endoneurium) can guide the regenerating nerve fibres to their target. Good potential for recovery; nerve fibre regrowth is at 1 mm per day.
- Neurotmesis – complete division of the nerve, nerve sheath and nerve fibre. Functionally poor outcome without surgical intervention to restore continuity of the nerve sheath.

| Degree | Pathology | Previously Called |
|---------------|--|--------------------------|
| 1 | Blocked flow of axoplasm / conduction block | Neuropraxia |
| 2 | Loss of axons but within its endoneurium | Axonotmesis |
| 3 | Loss of endoneurium and crossed regeneration | Neurotmesis |
| 4 | Injury to perineurium and scarring | Partial transection |
| 5 | Injury to epineurium and scarring | Complete transection |



Cerebellum
Get the balance right

Thank you

Best wishes!



BTR Orthopedics - 14-09-2025

Dr. Zainab Vora

1. What is the likely diagnosis based on the given image?

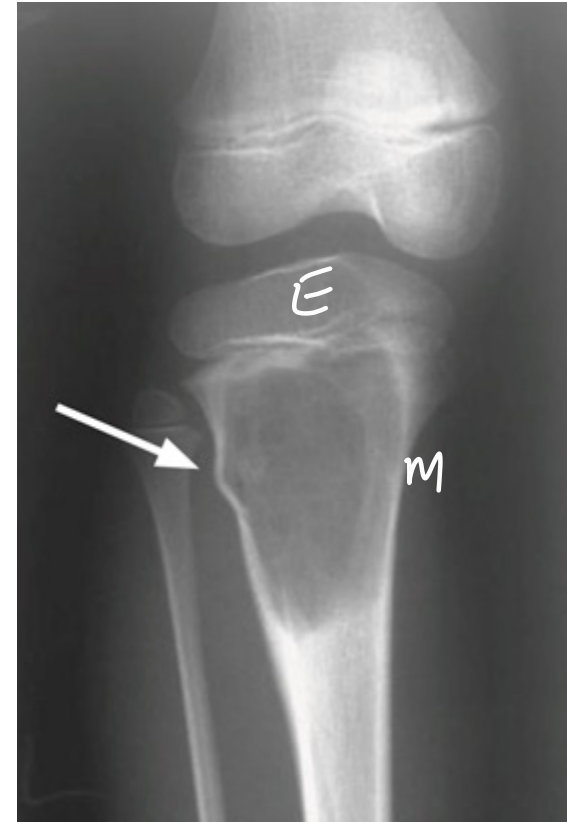
A. Giant cell tumour //

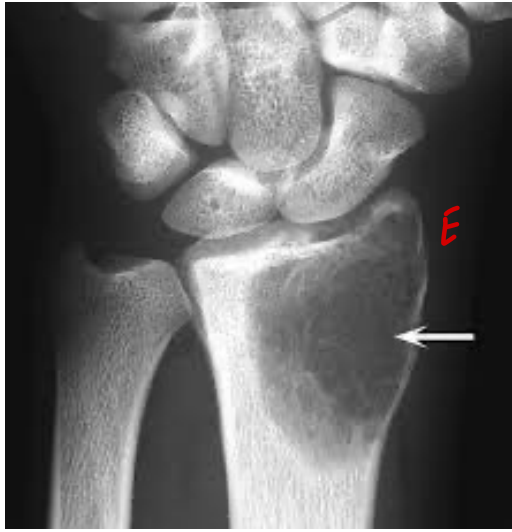B. Osteoblastoma

C. Aneurysmal bone cyst //

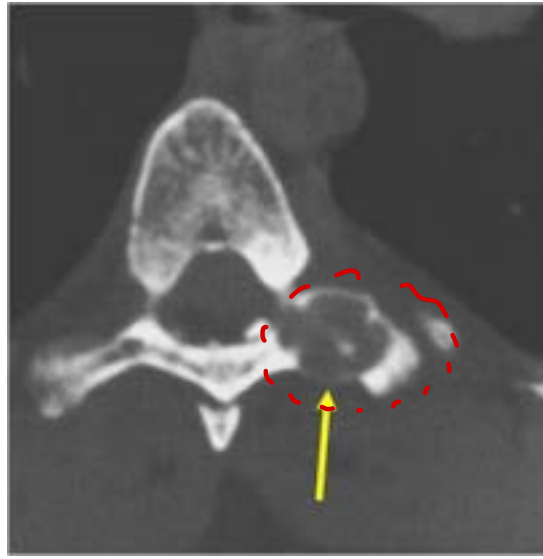D. Osteoid osteoma //

ECG ✓✓

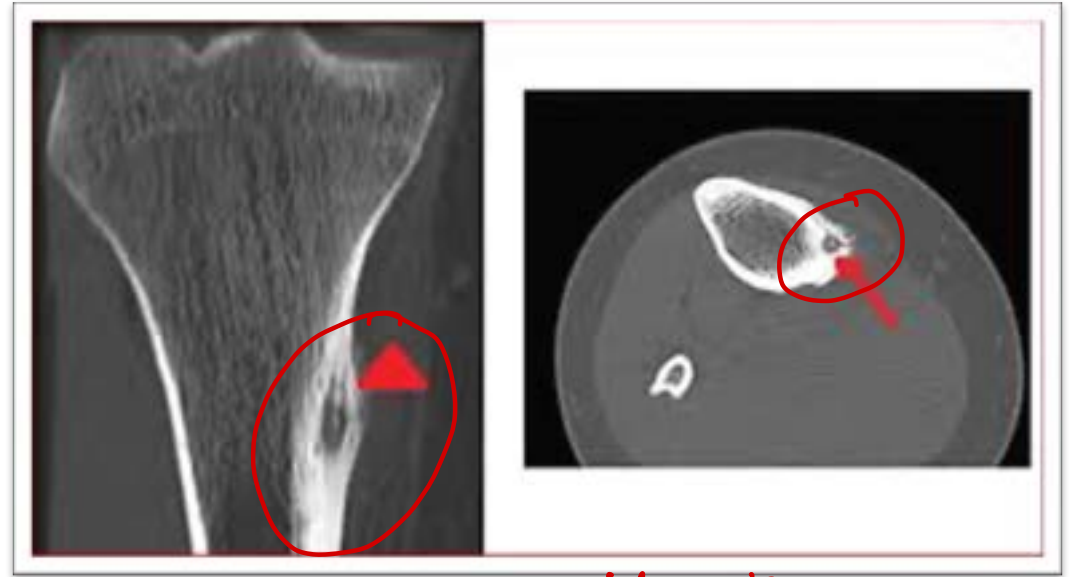



GCT



osteoblastoma



osteoid osteoma

2. Earliest way to detect development of compartment syndrome in a patient with cast is:

- A. Check radial pulse by displacing the cast
- B. Decreased response to analgesia
- C. Change in color of fingers
- D. Weakness in movement of the limb

earliest
↓
↑↑ pain passive stretch

3. A 28-year-old man presents with a 3-year history of gradually worsening low back pain, bilateral buttock pain, and stiffness. Symptoms are worse in the morning and relieved with stretching and hot showers. He also reports fatigue but denies fever, chills, night sweats, or weight loss. Physical examination reveals a stooped posture and tenderness over the lumbar spine midline and sacroiliac joints. Which of the following pathologic findings is most likely responsible for this patient's symptoms?

- A. Areas of bony erosions and new bone formation
- B. Areas of disorganized trabecular and cortical bone thickening
- C. Disc protrusion and thickening of the ligamentum flavum ~~XX~~
- D. Plasma cell infiltrate in bone marrow ~~MM~~

sacroiliitis

ankle spand

- Paget's



4. A 25-year-old woman comes to the emergency department after she awkwardly landed on her foot while playing volleyball. An X-ray of the foot is shown. The physician proceeds to immobilize her foot with a cast. Which of the structures is the most commonly injured in this patient?

~~A.~~ Anterior talofibular ligament

-mc

Lat

- Inversion

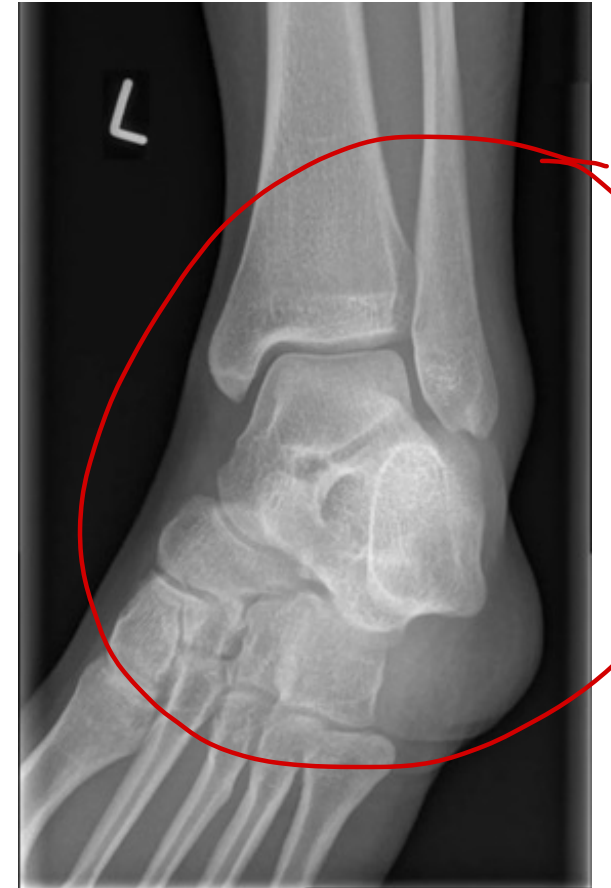B. Achilles tendon

C. Posterior talofibular ligament

~~*XX*~~

D. Peroneus brevis

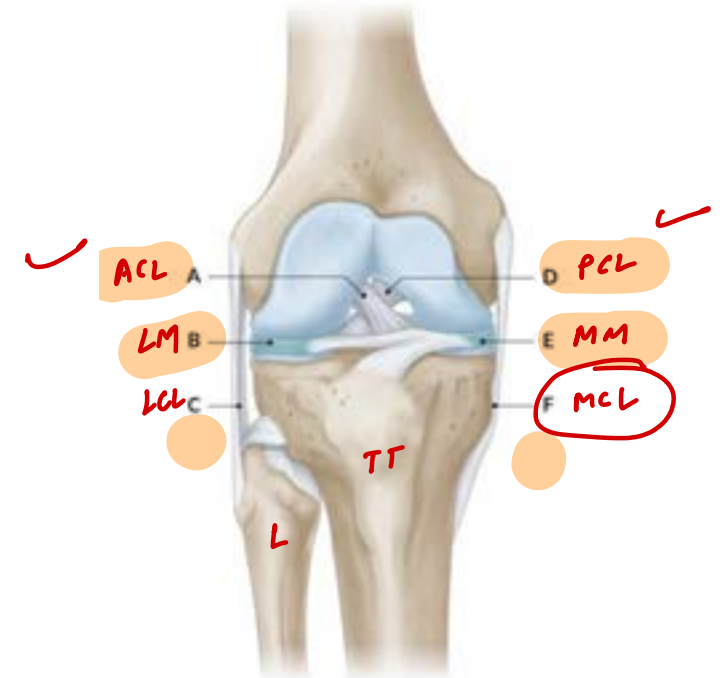
deltoid lig
└┘
eversion



5. A 27-year-old woman comes to the physician for a follow-up examination. Four days ago, she injured her right knee while playing basketball. Increased laxity of the right knee joint is noted when the knee is flexed to 30° and an inward pressure is applied at lateral thigh with one hand and outward pressure with medial ankle with the other hand. The examination finding in this patient is most likely caused by damage to which of the following structures?

- A. C
- ~~B. F~~
- C. A
- D. D

valgus



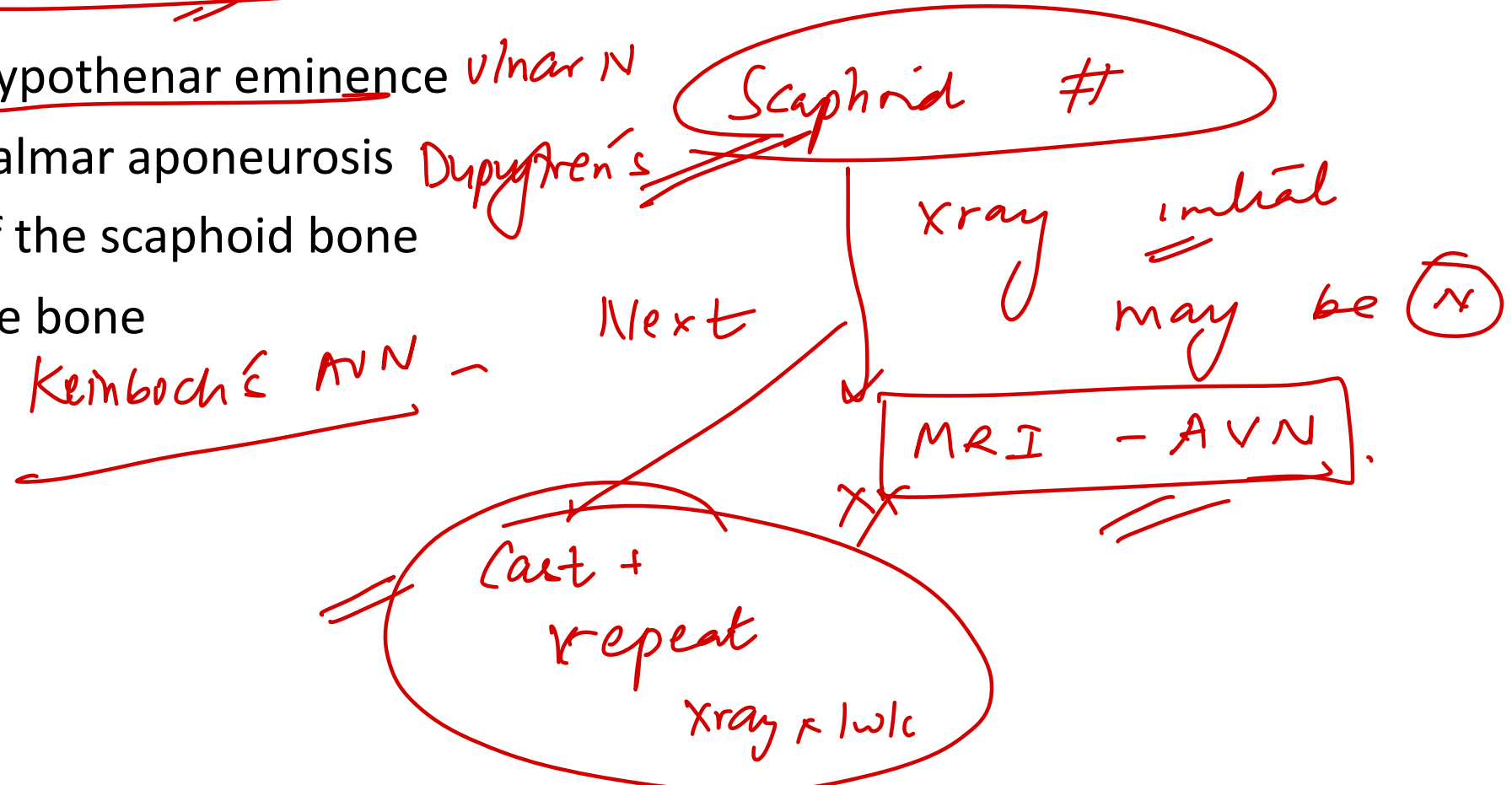
6. A 55-year-old woman comes to the office due to right shoulder pain for 4 months. She reports that the pain has improved since its onset, but now she has trouble with activities such as washing her hair or reaching the upper shelves of the kitchen cabinets. Heating pads and ice packs have not helped. She has had no fever, weight loss, or trauma. Medical history includes hypertension treated with lisinopril and hypothyroidism treated with levothyroxine. On examination, there is mild atrophy of the right deltoid muscle. Active and passive range of motion of the right shoulder is markedly reduced in abduction, flexion, and internal and external rotation compared to the left. Sensation in the upper extremities and strength in the hands and elbows are preserved. Which of the following is the best next step in management of this patient? Options:

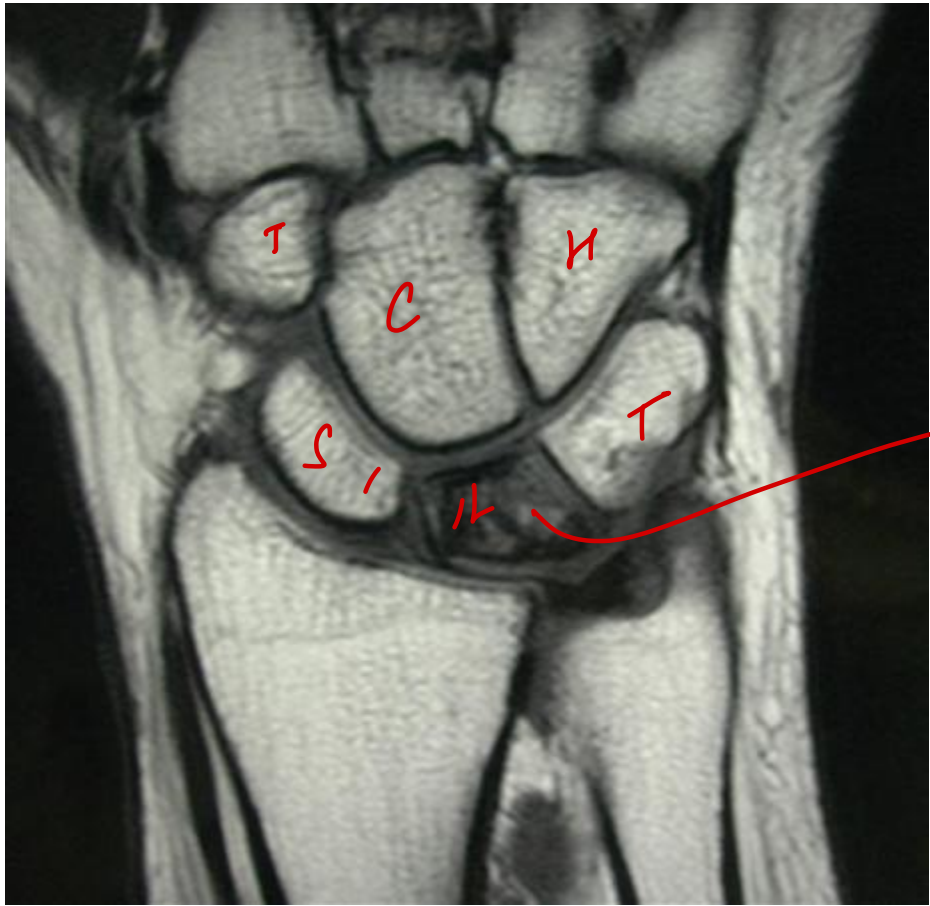
- A. Deltoid muscle biopsy *XX atrophy ↑↑*
- B. MRI of the cervical spine *paresthesia XX*
- C. Nerve conduction studies *XX*
- D. Range-of-motion exercises

FROZEN SHOULDER
(✓ DM)
adhesive capsulitis
✓ ALL ROM ↓

7. A 30-year-old woman presents to the physician with right wrist pain after a fall while jogging. Physical examination shows decreased grip strength and tenderness between the tendons of the extensor pollicis longus and extensor pollicis brevis. X-ray of the right wrist shows no abnormalities. This patient is at increased risk for which of the following complications?

- A. Hypesthesia of the hypothenar eminence
- B. Contracture of the palmar aponeurosis
- C. Avascular necrosis of the scaphoid bone
- D. Collapse of the lunate bone





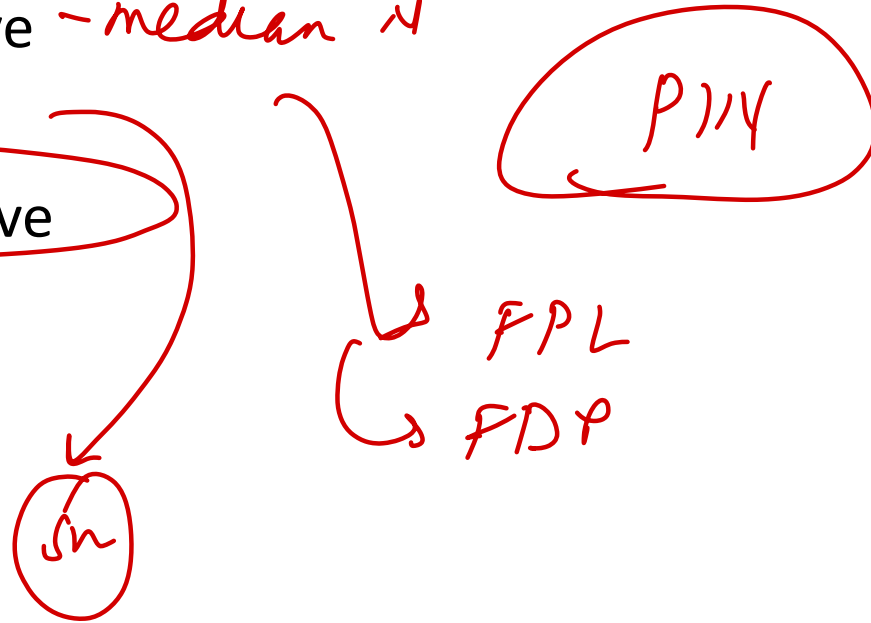
MRI

Lunate

→ Kienbock's

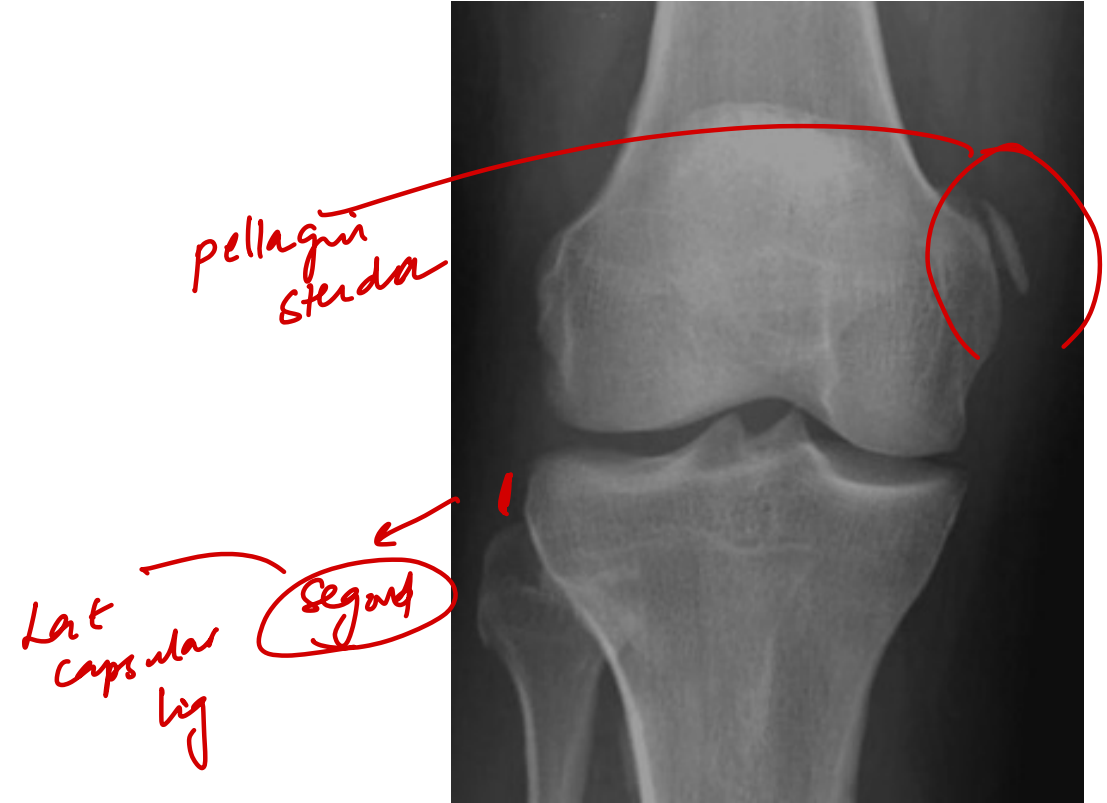
8. A 25-year-old woman visits the doctor with pain and weakness in her right forearm and hand for several months. Two years ago, she had a fracture in her ulnar shaft and a dislocation of her radial head that required surgery. On examination, there is mild tenderness a few centimeters distal to the lateral epicondyle. She has significant weakness when trying to extend her right middle finger and radial deviation on extension of the wrist. Sensation is normal. Which nerve is most likely affected in this patient?

- A. Anterior interosseous nerve - median N
- B. Superficial radial nerve
- C. Posterior interosseous nerve
- D. Ulnar nerve



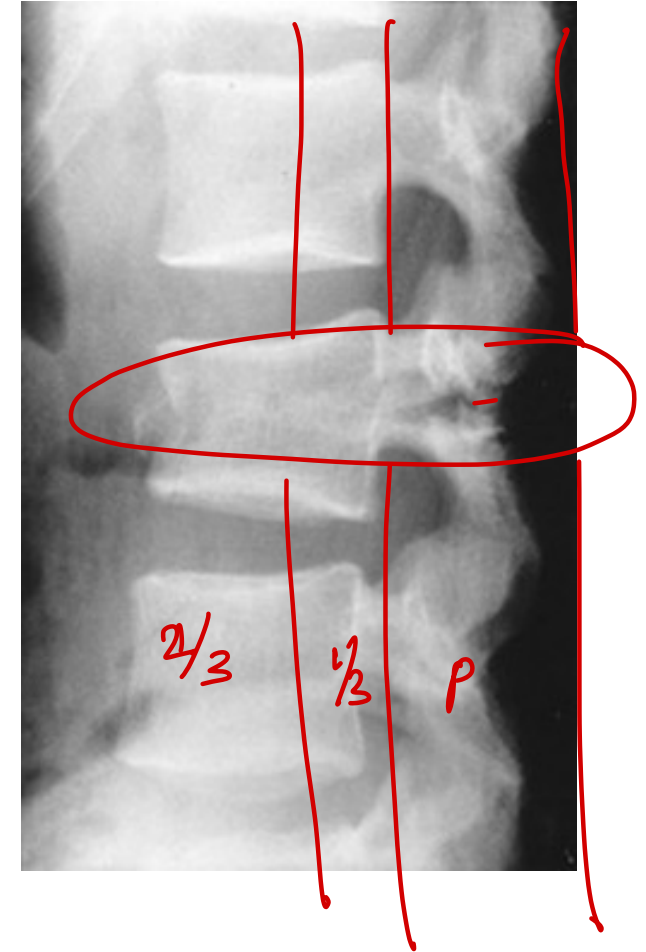
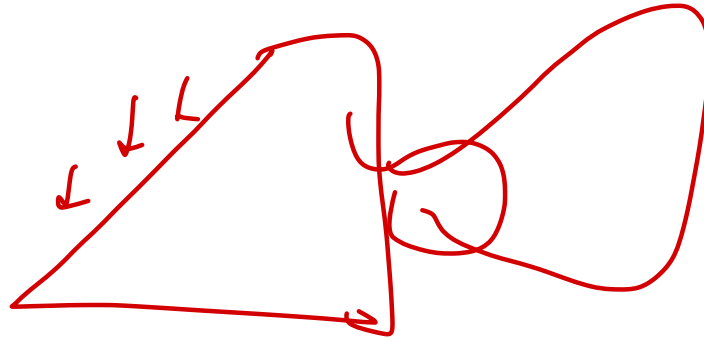
9. A 30-year-old male presents to the clinic with left knee pain and instability following a previous injury. Xray is shown below. Which ligament is most likely involved based on this finding?

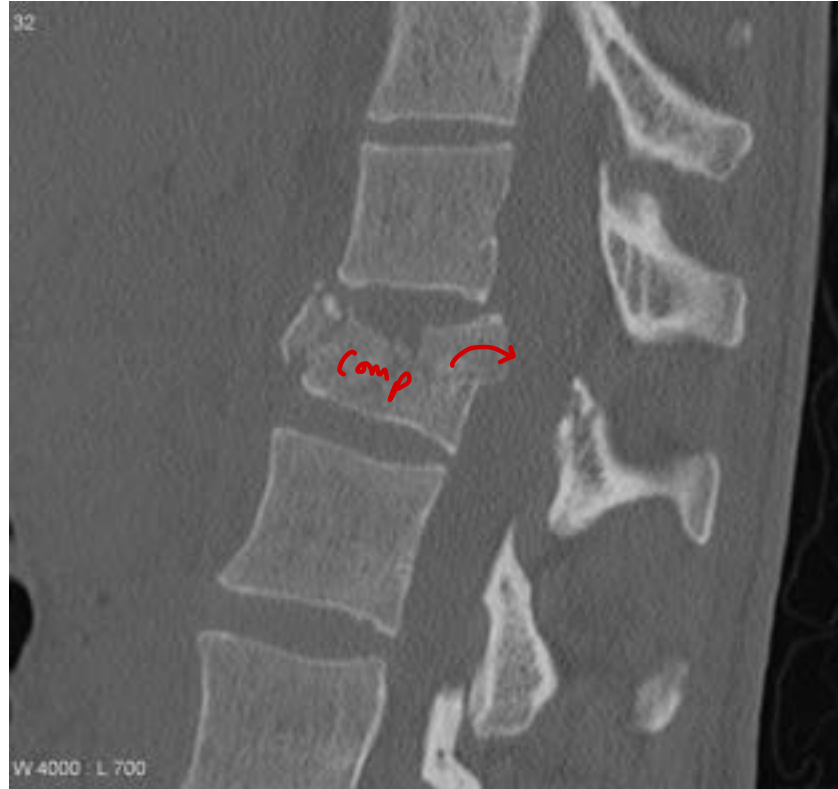- A. ACL
- B. PCL
- C. Lateral meniscus
- D. MCL**



10. A patient presented with severe back ache and the following x-ray after an RTA. Diagnose the fracture present.

- A. Burst fracture ✓
- B. Chance fracture ✓
- C. Compression fracture
- D. Fracture of spinous process ✓





BURST #

1
Compression # +
retropulsion

11. A 75-year-old woman presents to the clinic after a fall. She complains of right hip and thigh pain. Examination reveals that her right leg is shorter than her left and externally rotated. Which of the following pathological changes is most likely to be present in this patient?

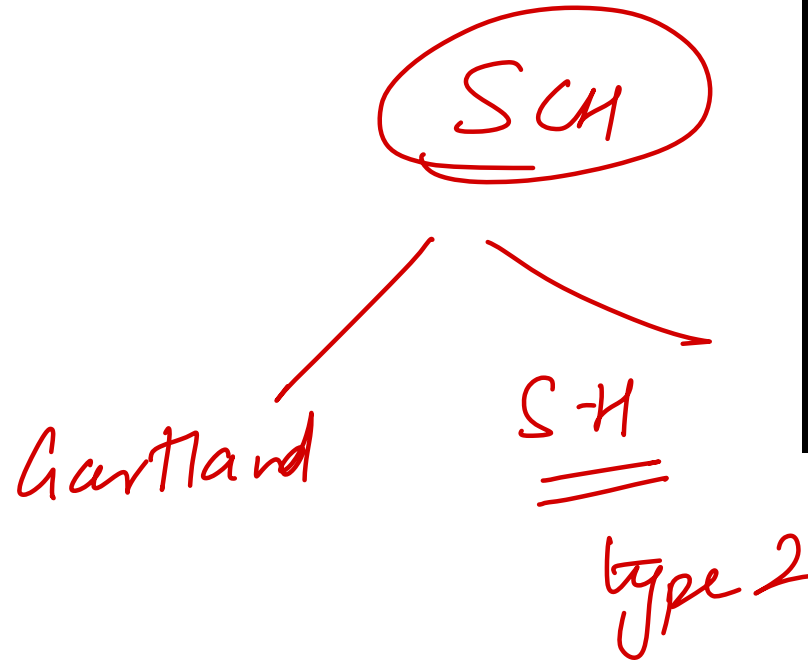
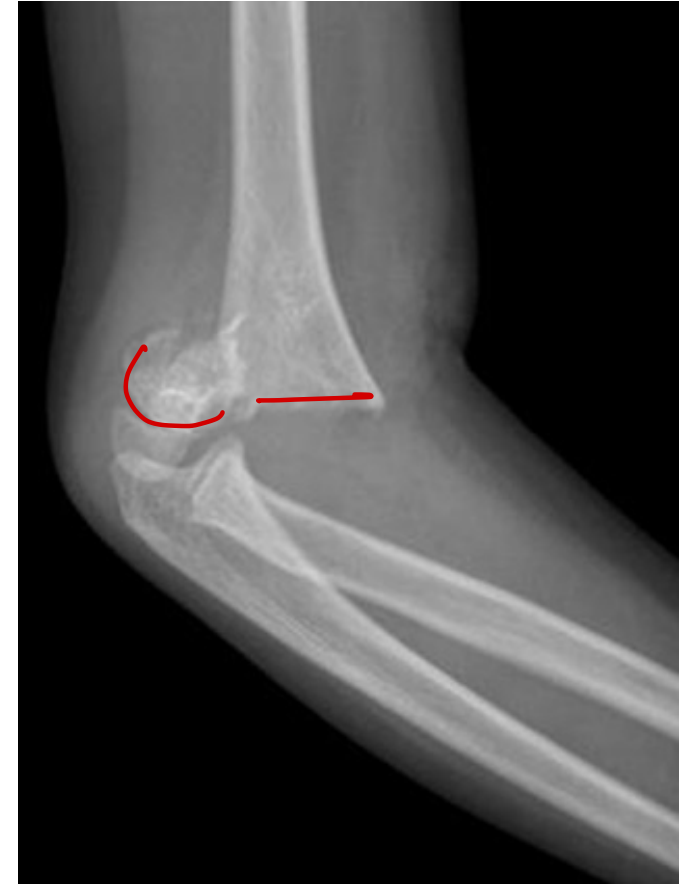- A. Cortical bone overgrowth and sclerosis due to defective osteoclasts → osteopetrosis
- B. Impaired mineralization of osteoid and hyperactive osteoblasts → Rickets / osteomalacia
- C. ✓ Decreased cortical and trabecular bone mass with normal bone mineralization
- D. Woven and lamellar bone mosaic pattern due to increased osteoclast and osteoblast activity resulting in bone of low quality → Paget's

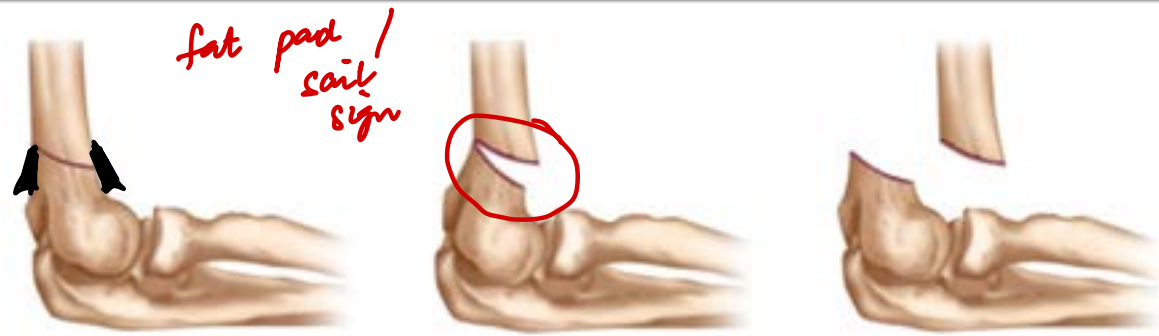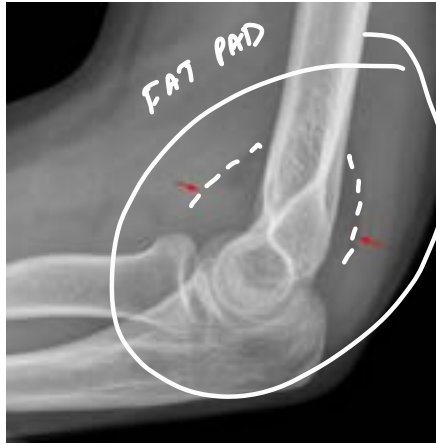osteoporosis

12. Identify the classification used and grade of the shown injury in a child

- A. ✓ Gartland's classification Type III
- B. ~~Salter-Harris classification Type III~~
- C. ~~Gartland's classification Type IV~~
- D. ~~Salter-Harris classification Type IV~~

NEET 1/24





Type I

Type II

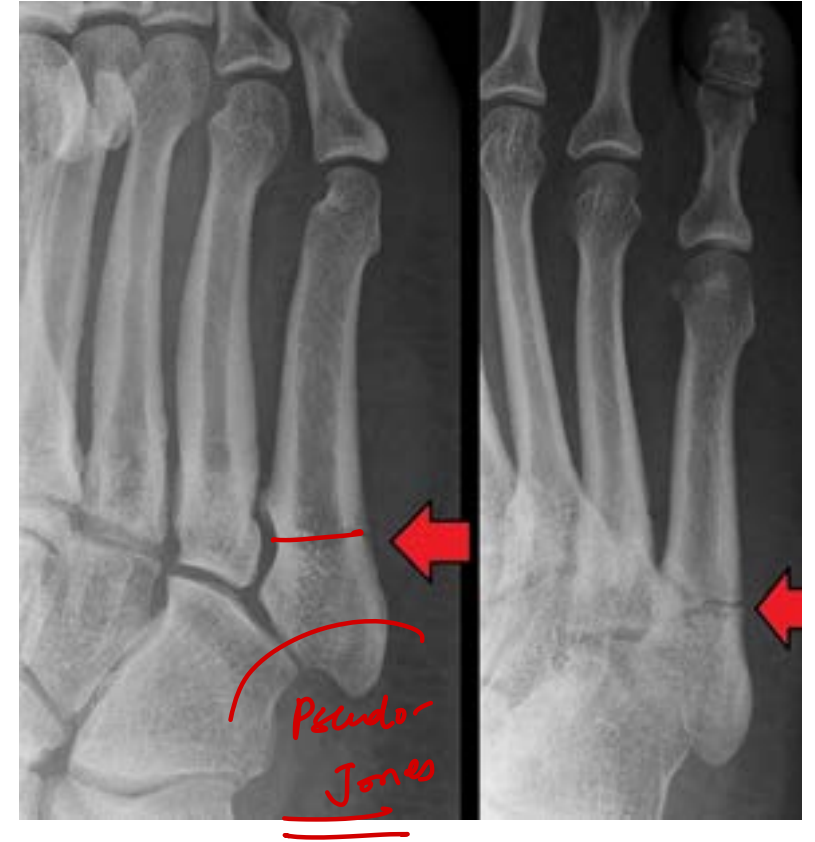Type III

| | |
|-----------|---|
| Type I | Non-displaced |
| Type II A | Intact posterior cortex, hinged in extension. No rotation or translation. |
| Type II B | Intact posterior cortex, hinged in extension, with some degree of rotational displacement or translation. |
| Type III | Complete displacement. |

13. Identify the fracture and mention the duration of below-knee POP cast applied for the following injury?

- A. Jones fracture; 2-3 weeks
- B. Pseudo-Jones fracture; 3-5 weeks
- C. Jones fracture; 6-8 weeks**
- D. Pseudo-Jones fracture; 6-8 weeks

NEET
124



14. A 19-year-old male presents with localized bone pain in the tibia. Imaging reveals a small radiolucent lesion surrounded by dense reactive sclerosis. The pain improves with NSAIDs. Which of the following is a histological feature of the most likely diagnosis?

A. Trabeculae of woven bone surrounded by fibrovascular stroma

B. Malignant osteoid production with atypical mitoses

C. Multinucleated giant cells surrounding hemorrhagic spaces

D. Fibrous tissue with scattered irregular bony trabeculae

metastasis

osteoid

osteoma

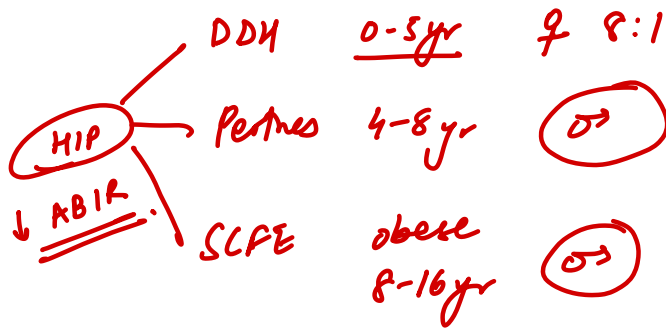
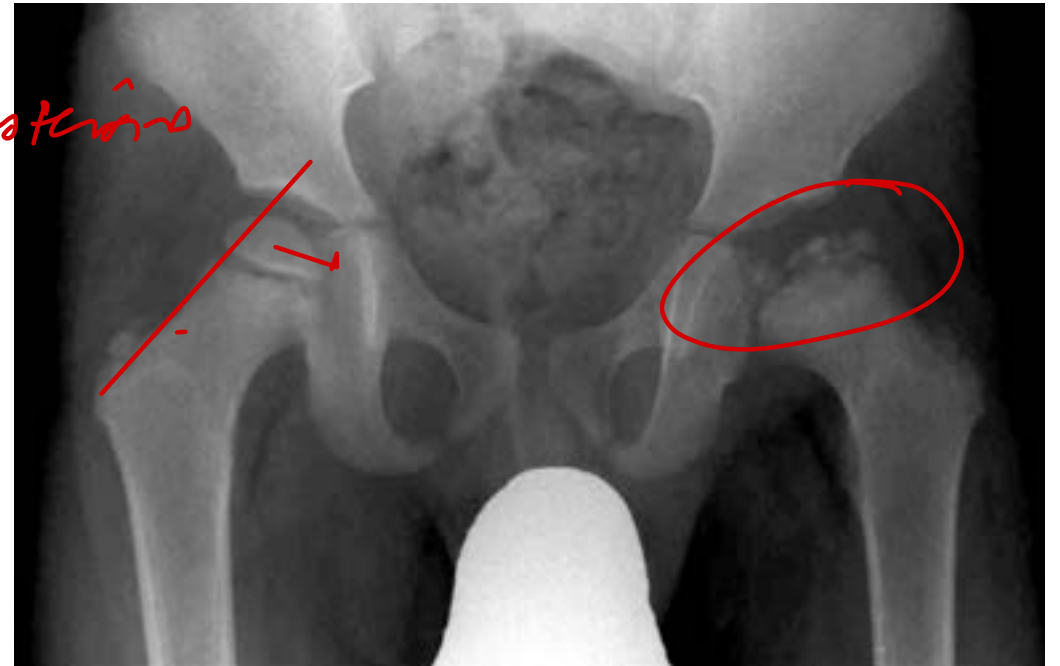
XX OS

GCT

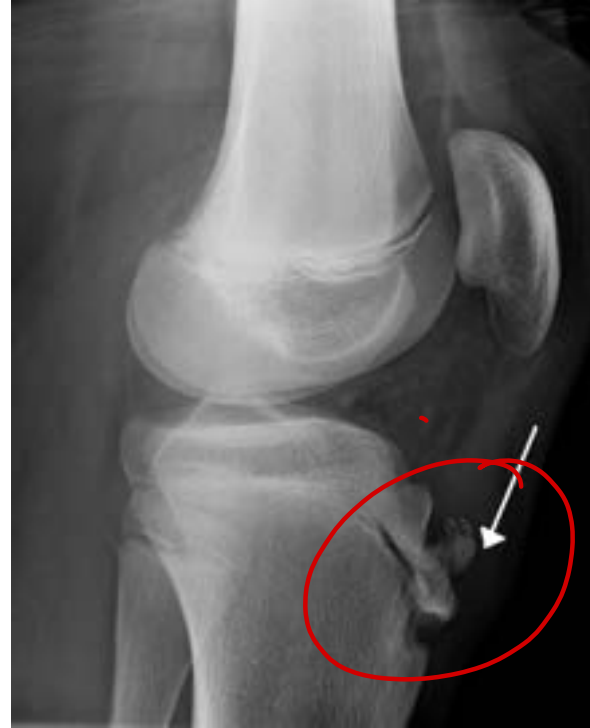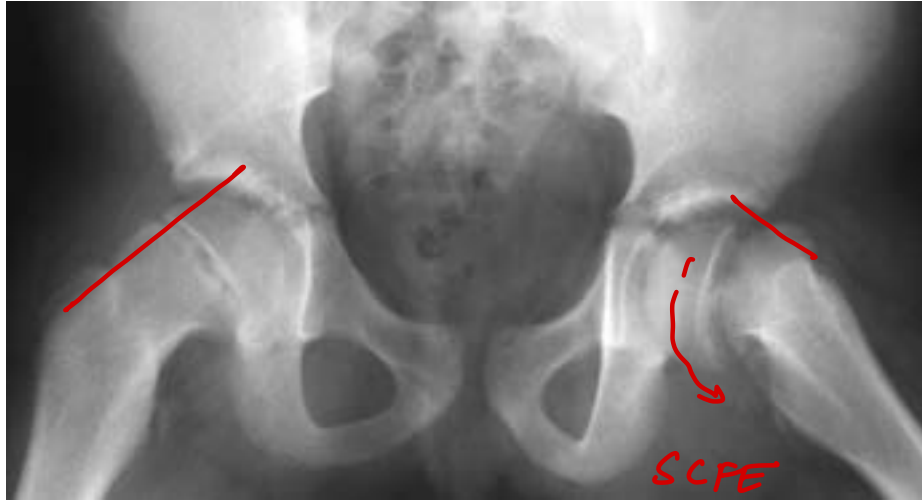
FD

15. A 6-year-old boy presents to the clinic with a 2-week history of limping due to right hip pain, which radiates to the knee. The pain increases with walking. He has no history of fever, cough, or recent infections. On examination, there is a restricted range of motion in the right hip during internal rotation and abduction, and pain is elicited during these movements. What is the most likely diagnosis?

- A. ~~Legg-Calvé-Perthes disease~~
- B. Septic arthritis toxic ↑ fever ↑ Jt dysfunction
- C. Osgood-Schlatter disease ~~XX~~
- D. Slipped capital femoral epiphysis




NEET / 25



Osgood-Schlatter

16. Identify the implant shown in the image used for treatment of proximal femoral fracture.

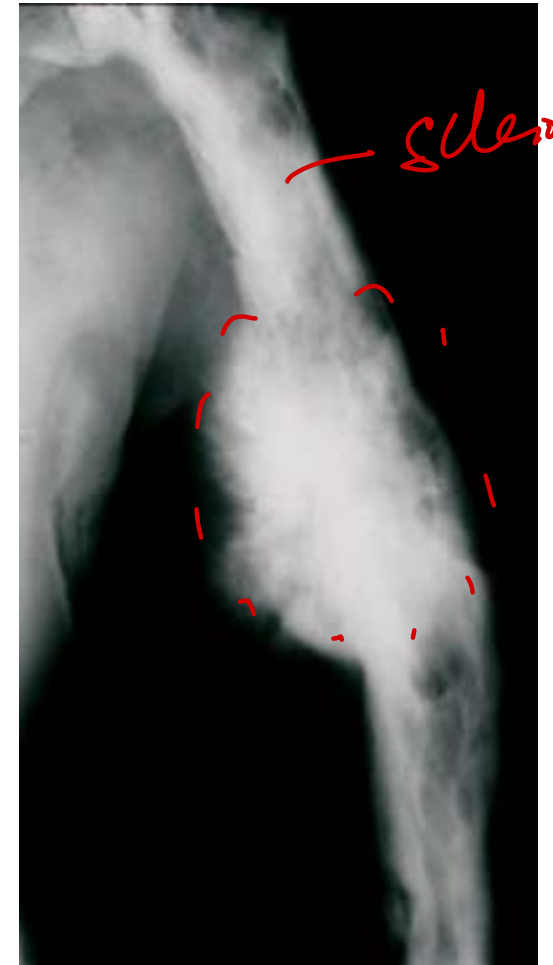
- A. Dynamic hip screw
- B. Dynamic condylar plate
- C. Proximal femoral nail
- D. Limited contact condylar plate



17. A 68-year-old man comes to the physician because of a 5-month history of undulating, dull pain in his right leg. Physical examination shows a tender, round mass located above the right knee on the anterior aspect of the thigh. An X-ray of the right thigh is shown. Which of the following is the strongest predisposing factor for this patient's condition?

- A. Hyperparathyroidism ~~XXXX~~ *Brown tumors*
- B. t(11;22) translocation *E/S*
- C. RB gene mutation ~~XXXX~~ *child*
- D. Paget disease of bone *2° osteosarcoma*

RT



18. A 32-year-old man comes to the physician because of a 6-week history of left shoulder pain, numbness, and tingling in his left hand. He mentions that the symptoms worsen when he raises his arm above his head. He works as a construction worker, frequently lifting heavy tools. Physical examination reveals decreased fine touch in the 4th and 5th fingers of the left hand and weakened grip strength on the left side. Palpation of the neck reveals diffuse pain. The patient's left arm is held in abduction, extension, and external rotation, and he is instructed to turn his head toward it while breathing deeply, causing a decreased radial pulse on the left side. Which of the following is the most likely cause of the patient's findings?

- A. Median nerve compression at the wrist
- B. Left rotator cuff tendinopathy
- C. C8 nerve root compression
- D. Anterior scalene muscle hypertrophy

radicular

parasthesia

Adson

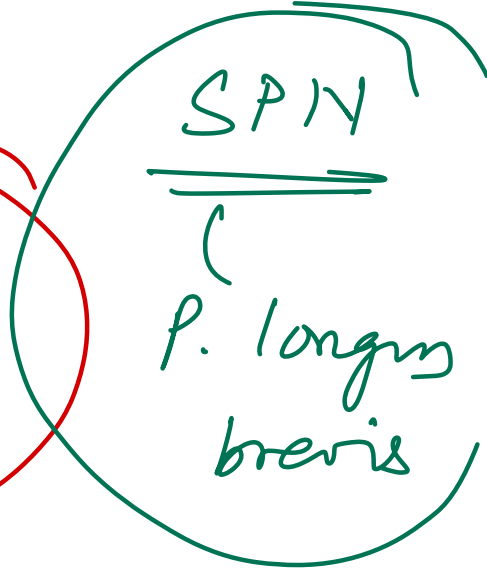

TOS

C8/T1

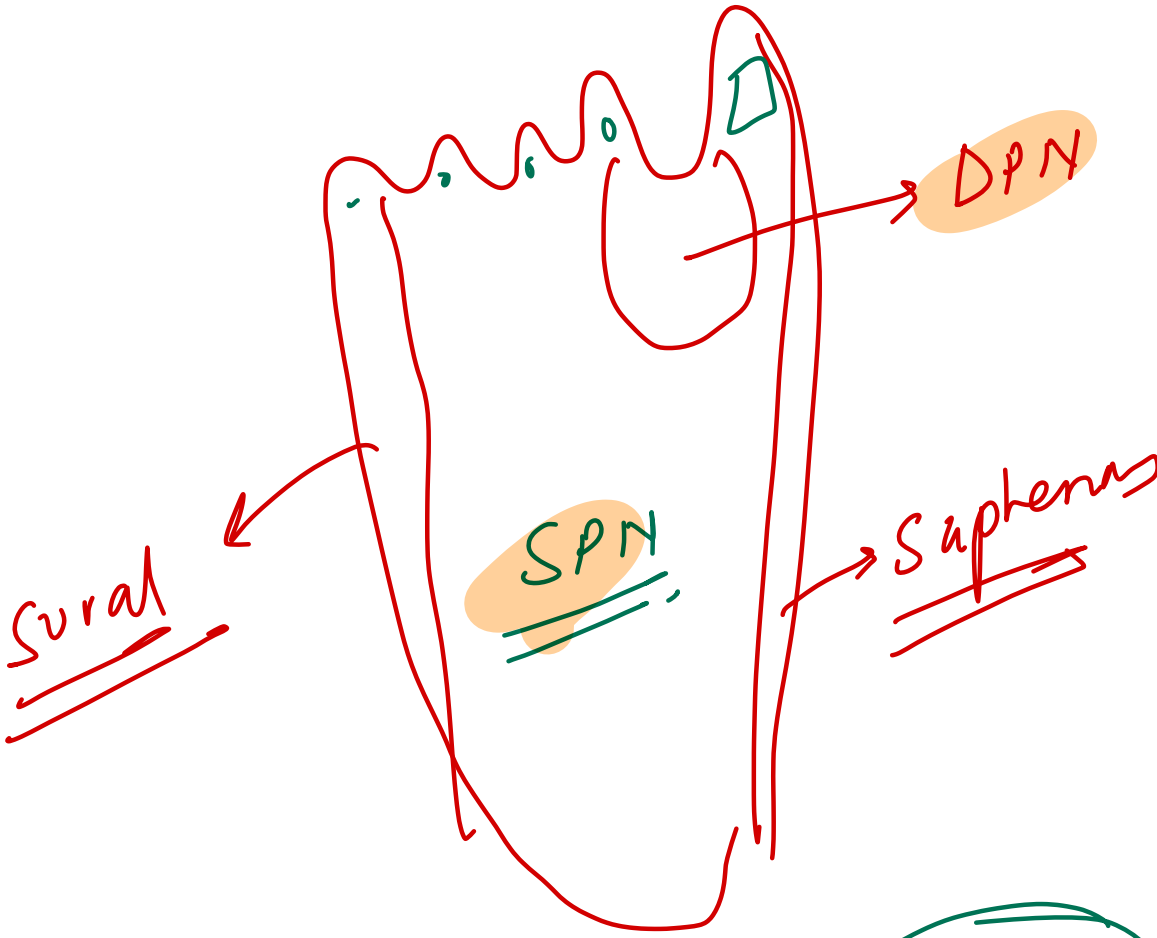
Trunk

19. A 32-year-old woman is brought to the emergency department 4 hours after being bitten by a venomous snake. Her pulse is 132/min, and her blood pressure is 102/79 mm Hg. Examination shows right lower leg swelling, ecchymosis, and blistering. Right ankle dorsiflexion elicits severe pain. A manometer inserted into the lateral compartment of the lower leg reveals an intracompartmental pressure of 68 mm Hg. In addition to administration of antivenom, the patient undergoes fasciotomy. Two weeks later, she reports difficulty walking. Neurologic examination reveals a loss of sensation over the lower part of the lateral side of the right leg and the dorsum of the right foot. Right foot eversion is 1/5. There is no weakness in dorsiflexion. Which of the following nerves is most likely injured in this patient?

- A. Deep peroneal nerve → dorsiflexion
- B. Tibial nerve → plantar flexion
- C. Superficial peroneal nerve
- D. Saphenous nerve



P. tertius → DP IV



Sole

→ Sural

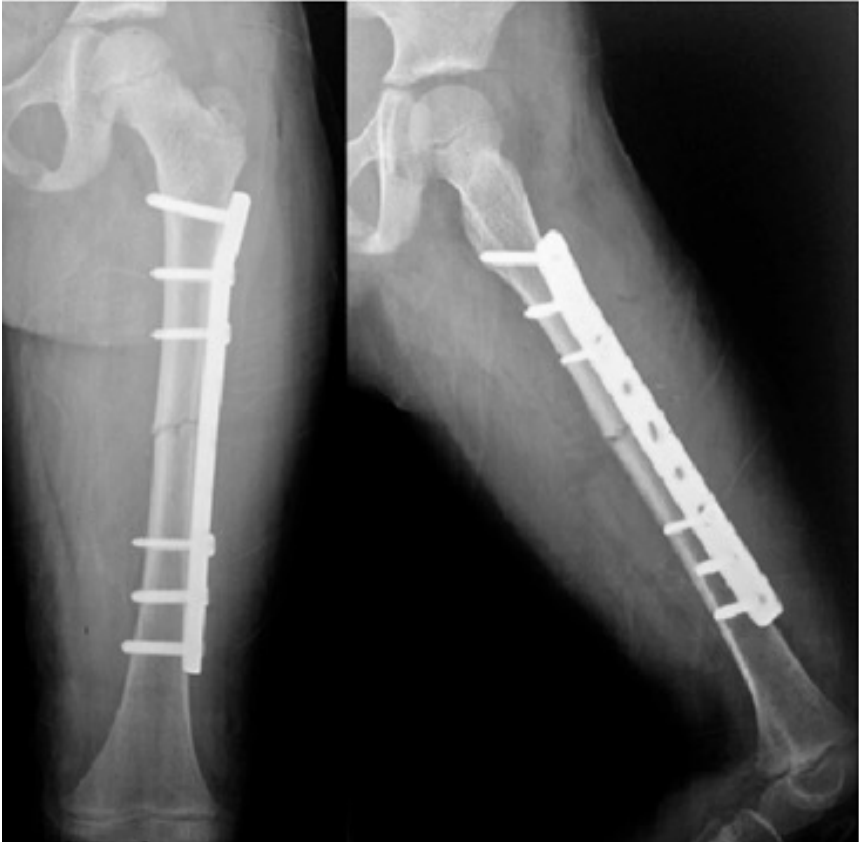medial / Lat
/ plantar N
↓
tibial N

20. A child sustained a fracture after a fall. The post-op x-ray is shown below. The fracture will heal by which mechanism? (NEET PG 2024)

- A. Creeping substitution
- B. Intramembranous ossification
- C. Primary healing
- D. Secondary healing

C. Primary healing - (x) callus - (x) mvk
- mvk - ✓ callus

nail



plate

✓ Primary bone healing: No callus

✓ Secondary bone healing: Callus +

Callus earliest: 3wk

Delayed union: 6mon

Non-union: 9mon

21. Arrange the following external fixators used for treatment of fracture of tibia in order of increasing stability: PyQ.

I. Ilizarov

II. Uniplanar frame with one rod

III. Biplanar frame

IV. Uniplanar frame with two rods

A. II, IV, III, I

B. I, III, II, IV

C. II, III, IV, I

D. I, II, III, IV

II - IV - III - I

22. Which of the following is not true about intracapsular fracture of femur neck?

- A. Displacement is less common than extracapsular fractures
- ~~B. Malunion is common complication~~
- C. Contour of greater trochanter is normal
- D. Tenderness is mainly present over the anterior joint line

Intracapsular
NOF
nonunion

extracapsular
ITF
malunion

23. Identify the correct statements

1. The most common complication of an untreated radial head dislocation is the cubitus valgus deformity at the elbow. (T) / LCH.

2. Seek kebab surgery / Sofield Miller Osteotomy is performed for Achondroplasia OI

3. Tartrate-resistant acid phosphatase (TRAP) is elevated in osteoporosis (T)

4. Posterior tibialis tendon is palpable behind the medial malleolus during inversion of the foot (T)

A. 1, 2, 3, 4

B. 1, 3

C. 1, 3, 4

D. 2, 3

- PTA
- PTV

(T)

24. 1-month-old girl is brought to the OPD for a routine newborn examination. Physical examination is shown below. When supine with the knees flexed, the left knee appears to be inferior to the right knee. Skin examination shows a nonblanching, blue-grey macule with indefinite borders over the sacrum. Which of the following is the most appropriate next step in management of this patient?

A. Reassurance *xx*

B. Skeletal survey *xx*

C. Ultrasound of hips *<6mm*

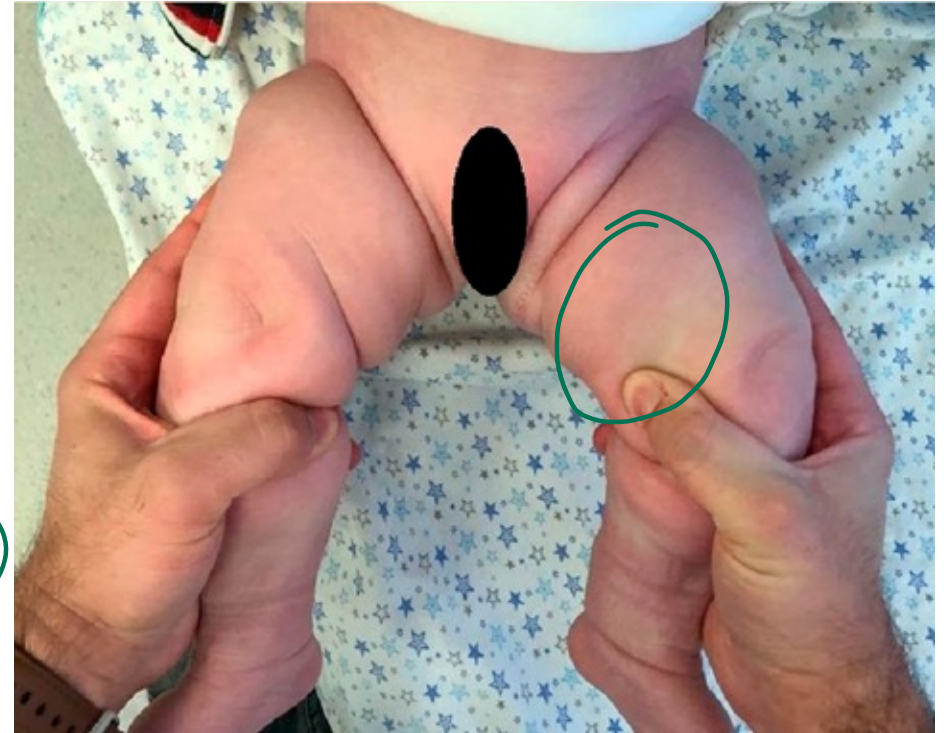
D. X-ray of hips *>6mm*

asymmetric



DDH

Allis / Galeazzi



25. Patient had difficulty in walking upstairs. When he was made to bear weight on right lower limb, the left-sided pelvis dropped down but when he was standing on the left lower limb, the right-sided pelvis moved up. Which of the following is the likely lesion?

- A. Right superior gluteal nerve palsy
- B. Left superior gluteal nerve palsy
- C. Right inferior gluteal nerve palsy → GI max
- D. Left inferior gluteal nerve palsy

DOZI

RT

26. What is the sequence of performing a Thomas test?

I. Passive flexion of affected hip

II. Active flexion of normal hip

III. Measure the flexion angle

IV. Checking for lumbar lordosis

A. I, II, III, IV

B. I, III, II, IV

C. II, III, IV, I

D. IV, II, I, III

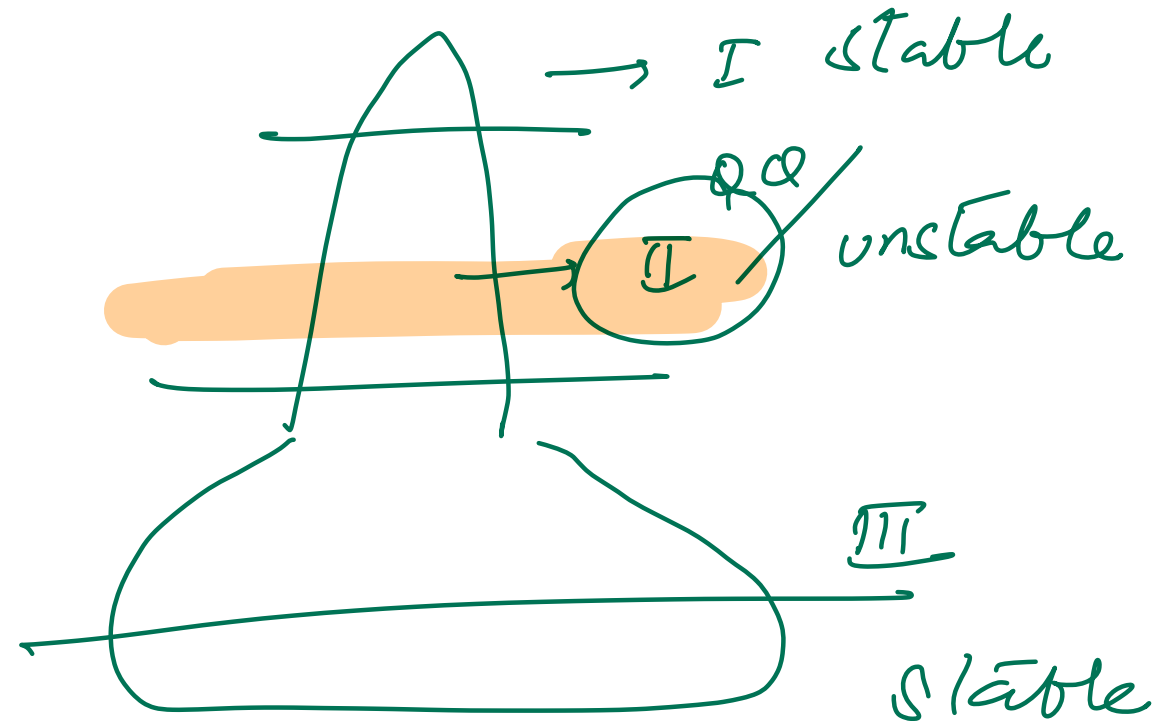
py 2

lordosis

III

27. Most dangerous type of odontoid fracture as per Anderson and D'Alonzo classification and its respective management is:

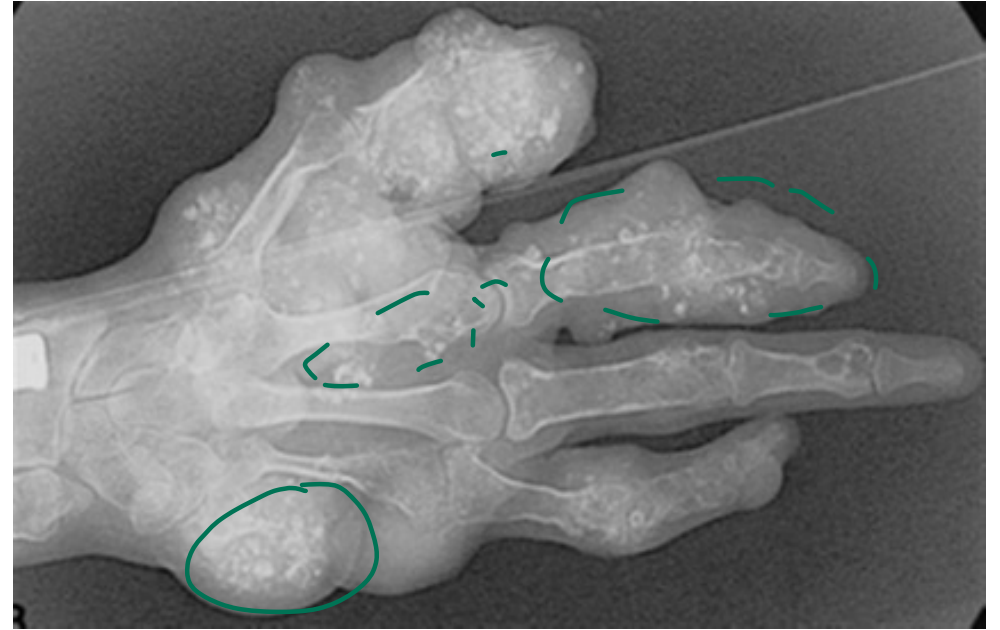
- A. Type I- immobilization in rigid collar
- B. Type II-screw fixation
- C. Type III-halo vest immobilization
- D. Type IV-open reduction internal fixation



28. What is the likely diagnosis based on the images shown?

- A. Mazzabarud syndrome → FD + myxomas
- B. Ollier disease
- C. Maffucci disease
- D. Osler-Weber-Rendu syndrome = HHT

AVM telangiectasia



29. 42-year-old woman comes to the AIIMS OPD due to right knee pain for the past 3 days. She was carrying a heavy backpack on a muddy trail when she tripped, twisting her leg. The next morning, she had swelling at the knee and significant medial knee pain with stairs and squatting. Which of the following is most likely to be found on examination of this patient's knee?

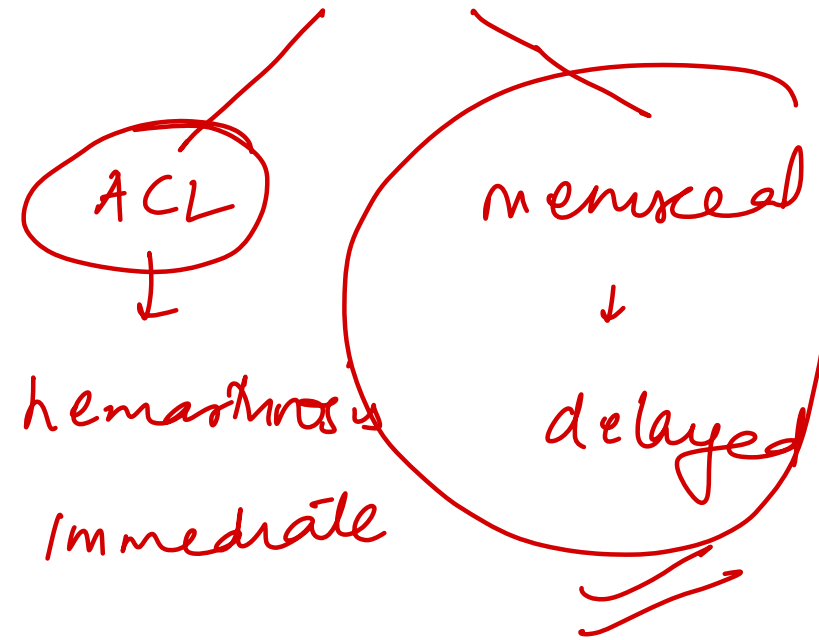
A. Anterior laxity of the tibia relative to the femur → ACL

B. Excessive valgus deviation with lower leg abduction MCL

C. Painful click during knee extension and external rotation

D. Tenderness at the medial knee below the joint line

↳ Pen anserinus bursitis





Apley's grinding



↓
Thesley



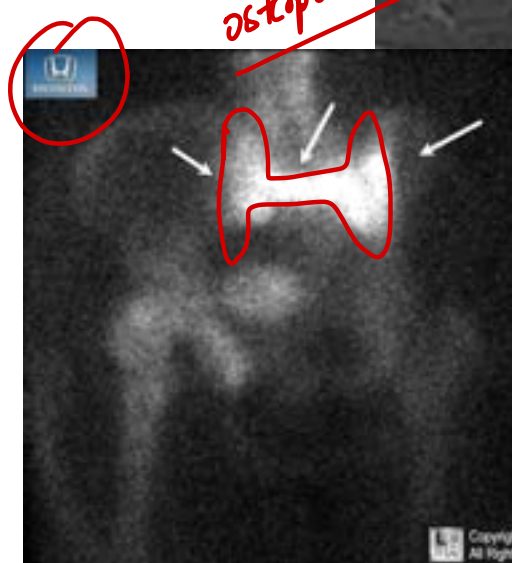
McMurray =

30. What other finding would be expected in this 25-year-old male with abnormal pelvis MRI?

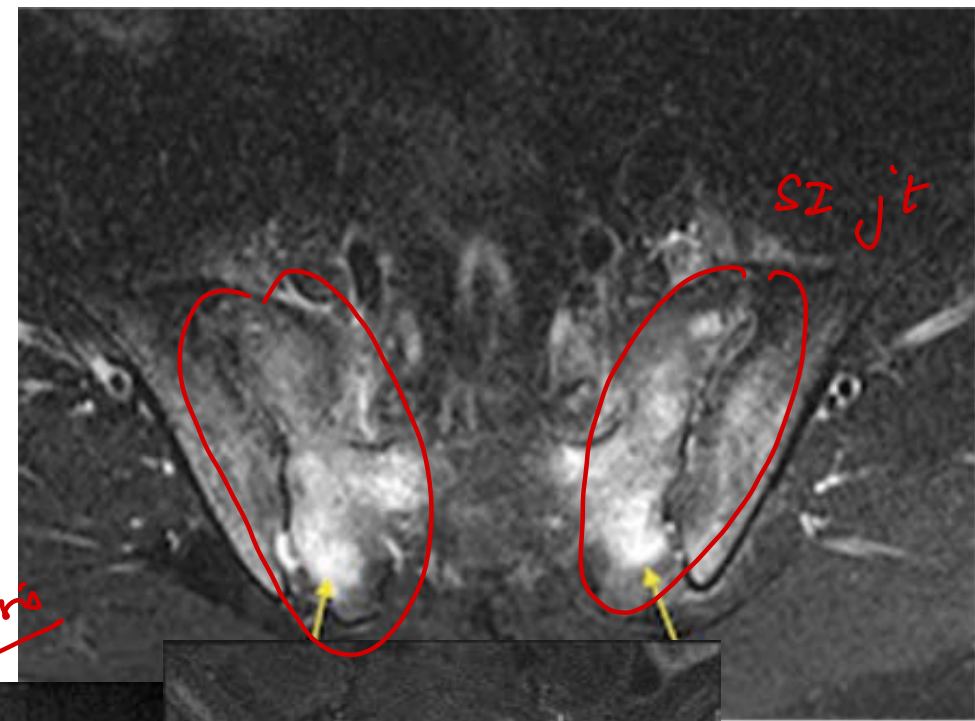
- A. Elevated RF *xx seroneg*
- B. ~~Acute painful red eye~~
- C. Atlanto-axial dislocation → **RA**
- D. IV disc calcification

ochronosis
alkaptonuria

ankle spread
IOC / *most on* → *MRI*



ochronosis



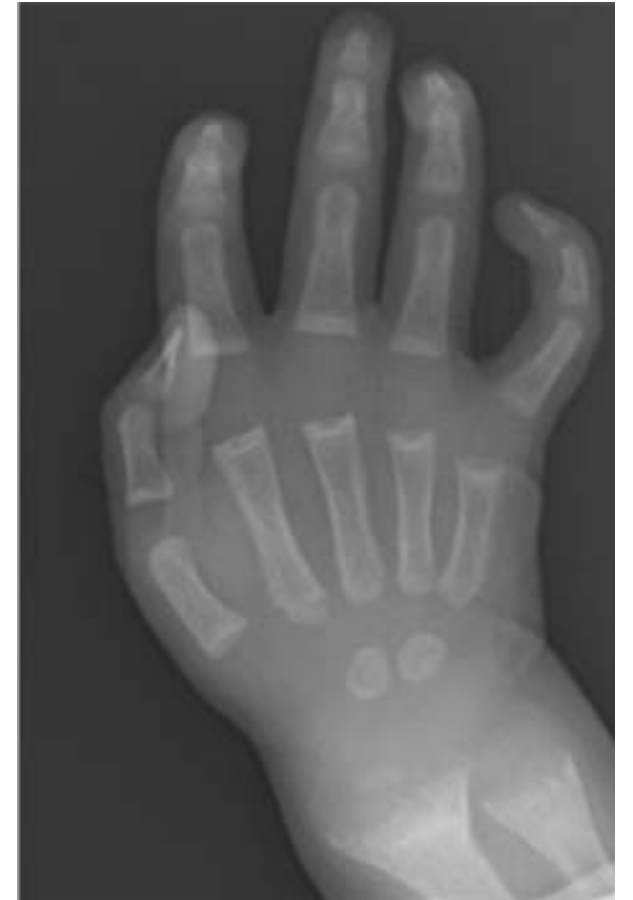Honda sign
↓
sacral

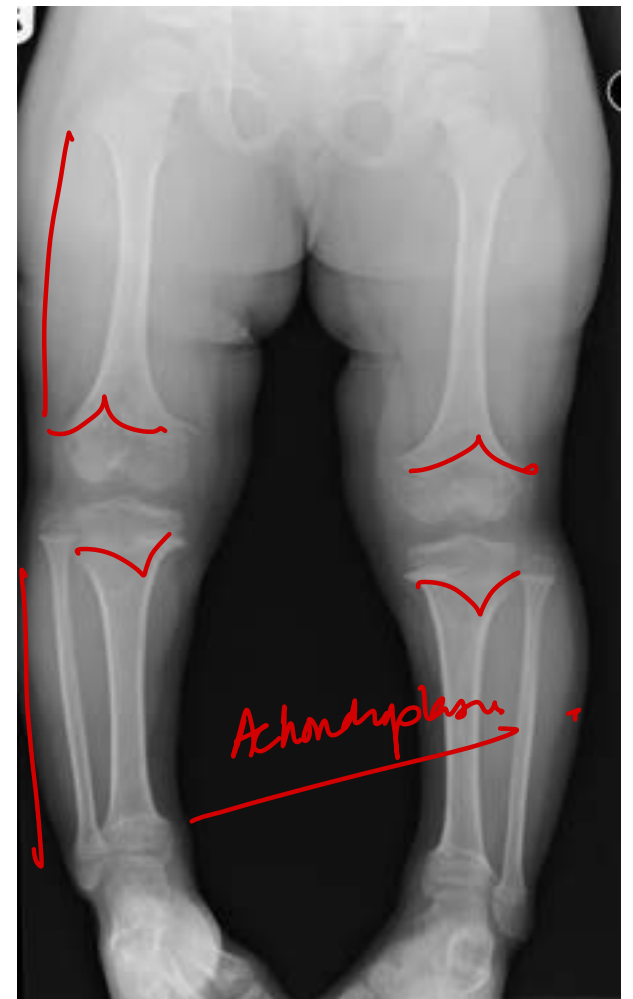
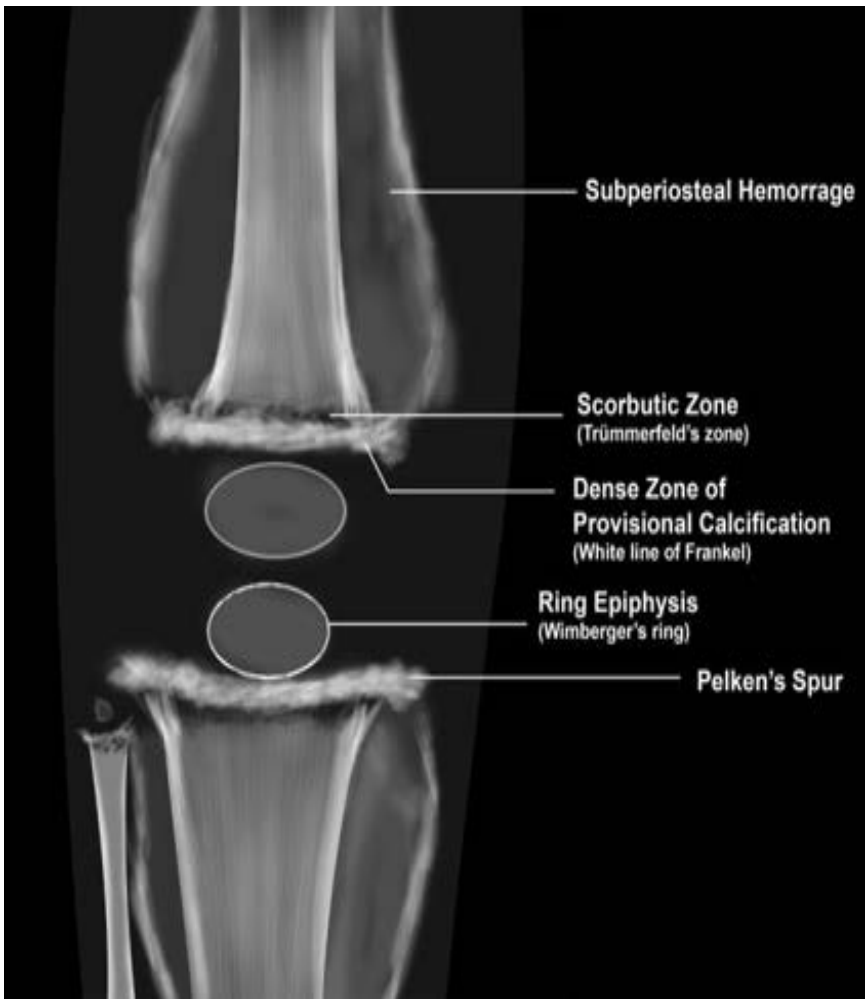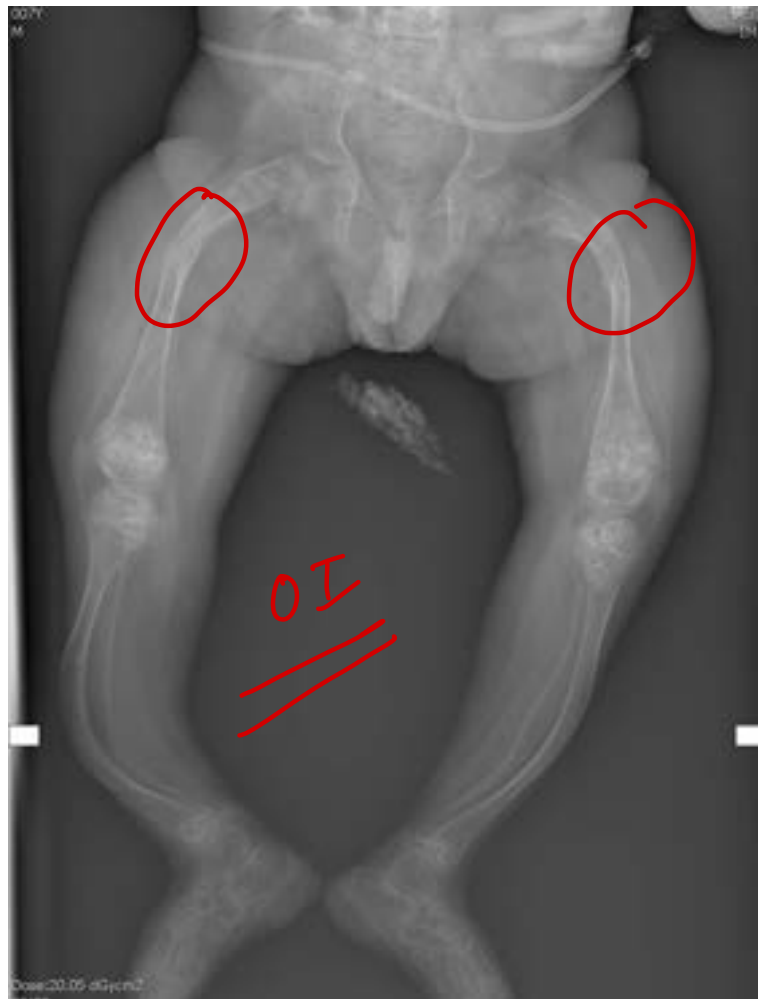
insufficiency
✓

Sacroiliitis

31. A child presented with difficulty in walking. The wrist radiograph is shown below. What is the diagnosis?

- A. Scurvy
- B. Osteogenesis imperfecta
- C. Rickets**
- D. Achondroplasia





32. A 25-year-old female presents with right heel pain since 3 months. She is a model by profession. There is no history of trauma. What is the likely diagnosis based on the MRI STIR image shown below?

A. Madelung deformity

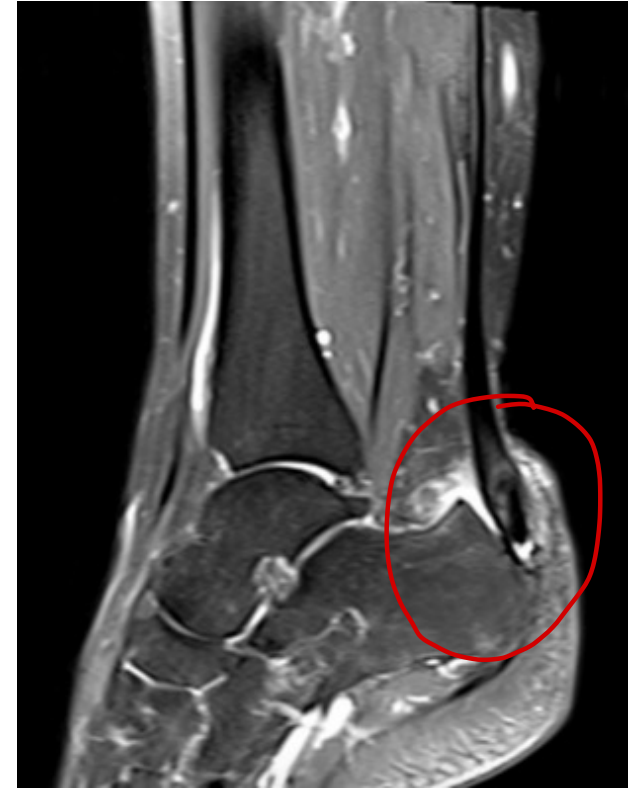B. Haglund deformity

C. Plantar fasciitis

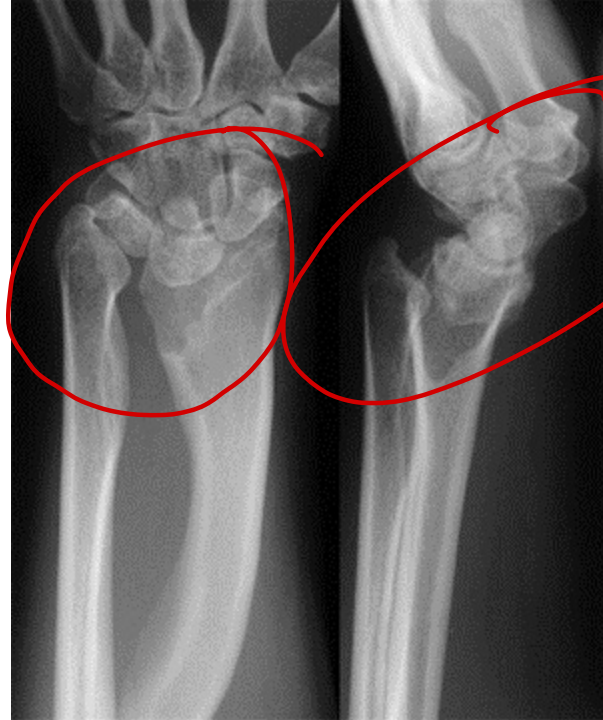D. Stress fracture

wrist

-heels



7



Madelung

33. A 22-year-old woman comes to the OPD for evaluation of new-onset foot pain. The pain is located at the heel and is most pronounced when she gets up from sitting after a long period of time. She enjoys running every evening for one hour. Direct pressure to the bottom of the heel elicits sharp pain, but mediolateral squeezing of the heel causes no discomfort. Which of the following is the most likely etiology of the patient's foot pain?

- A. Entrapment of the posterior tibial nerve
- B. Morton neuroma
- C. Stress fracture ~~xx~~
- D. Inflammation of the plantar aponeurosis

→ Tinel sign

Mulder sign

median plantar nerves

fibrosis

1st step

34. A 35-year-old female came with persistent back ache, not responding to conservative treatment. She has a history of heavy weight lifting 4 months back with progressively increasing pain that worsens on walking and starts radiating down her legs within 100m range of walking, she however feels no pain on climbing up the stairs. Most probable diagnosis is?

A. Vertebral osteoporotic compression fracture

B. PIVD *radicular*

C. Lumbar canal stenosis

D. PAD

tenderness

- 1st step

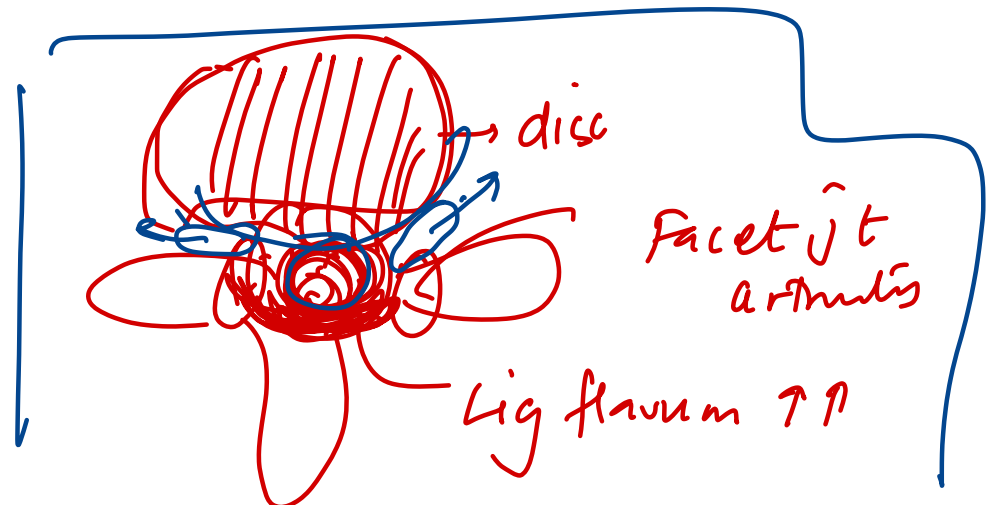
pye

Neurog claud

- Improves

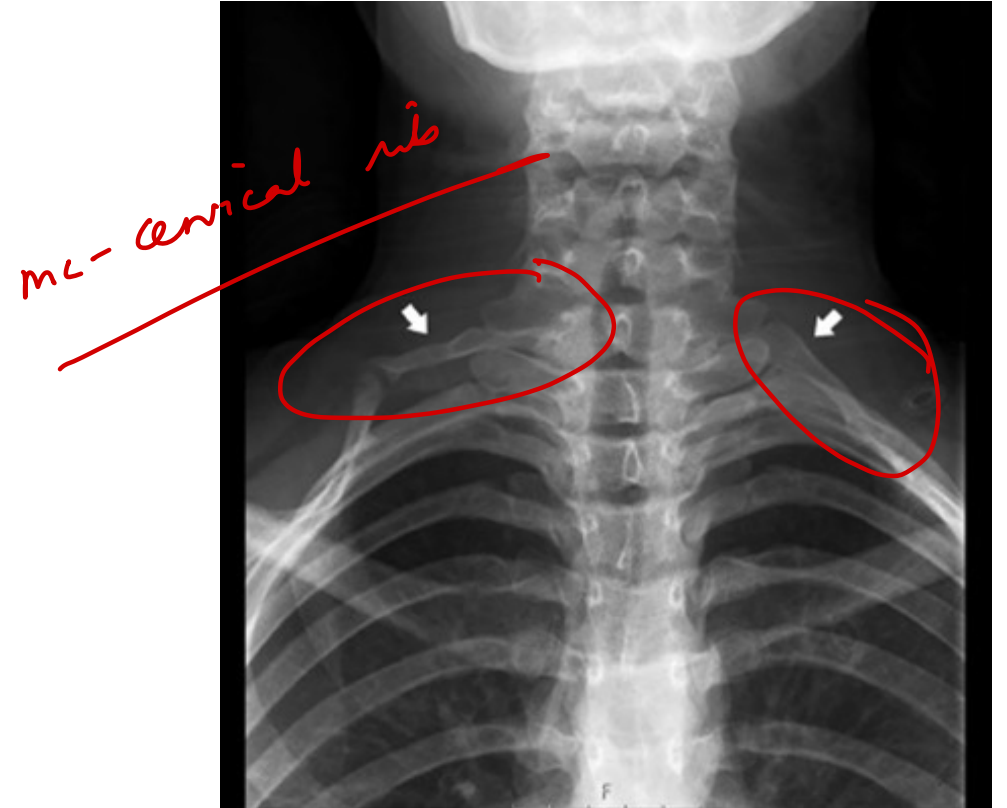
Cart

uphill



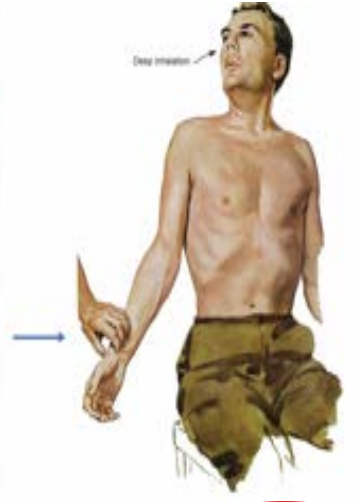35. A 45-year-old patient with suspected thoracic outlet syndrome is being examined. Hyperabduction of the arm on the affected side causes a reduction in the radial artery pulsation. X-ray is shown. What is this test known as?

- A. Adson's test
- B. Halstead's maneuver
- C. Roos's test
- D. Wright's test





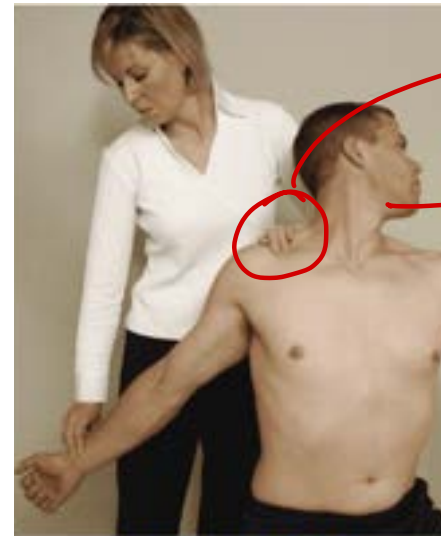
Ross



Adson



Weight



Costo clav
Compression

Haldstead

36. A young man, aged 25, arrived with complaints of difficulty in gripping a piece of paper between his fingers. Where is the probable location of the injury?

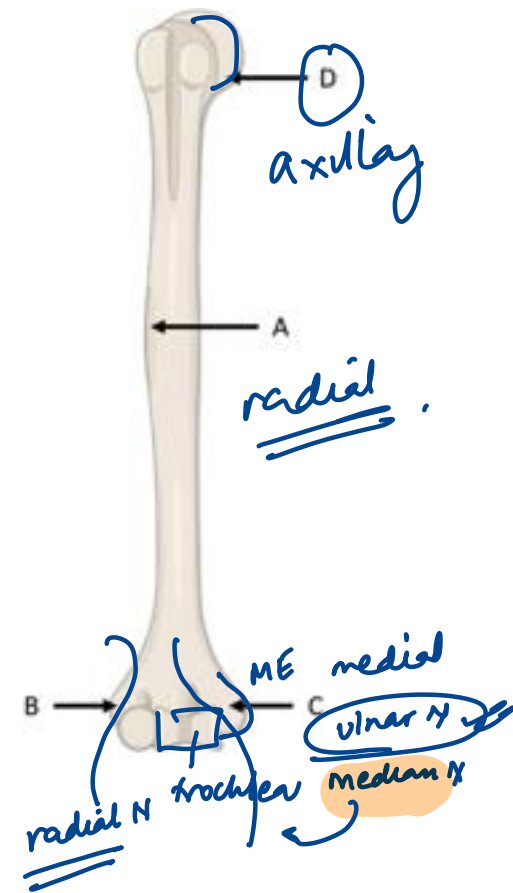
A. A

B. B

C. C

D. D

PAD



37. What is the likely diagnosis of the image shown below?

A. Coxa magna ~~XX~~

B. Coxa valga $>135^\circ$

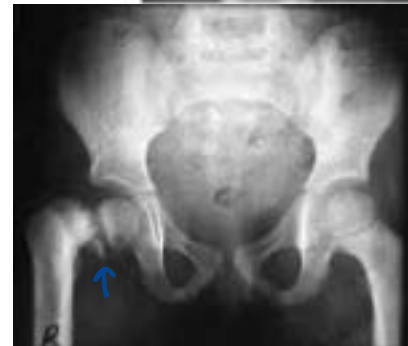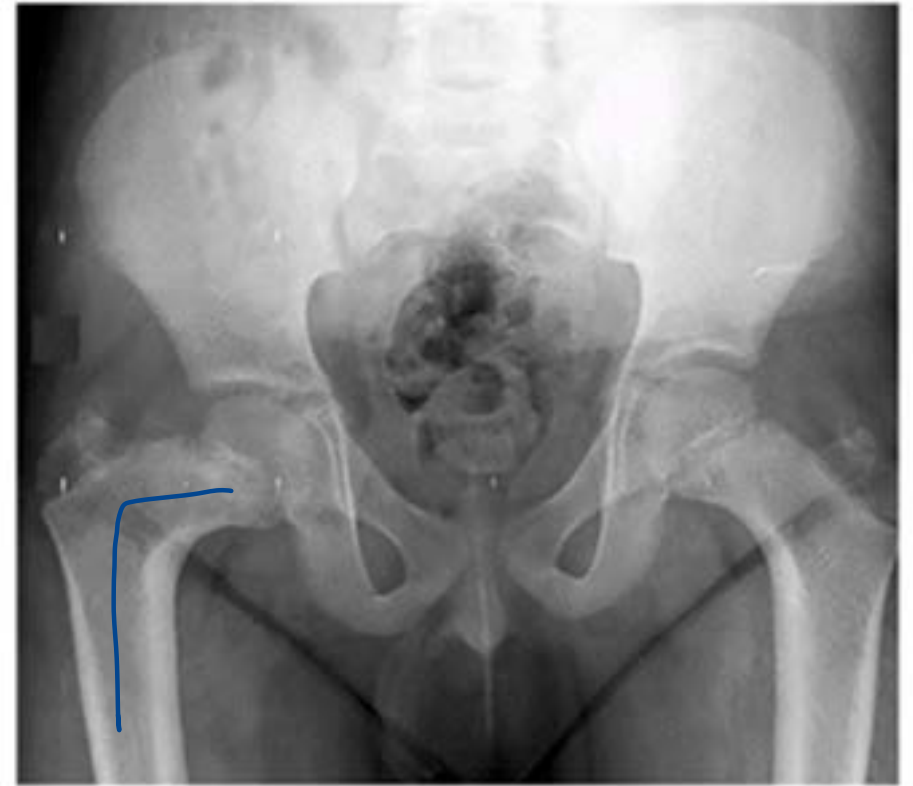
C. Coxa vara $<120^\circ$

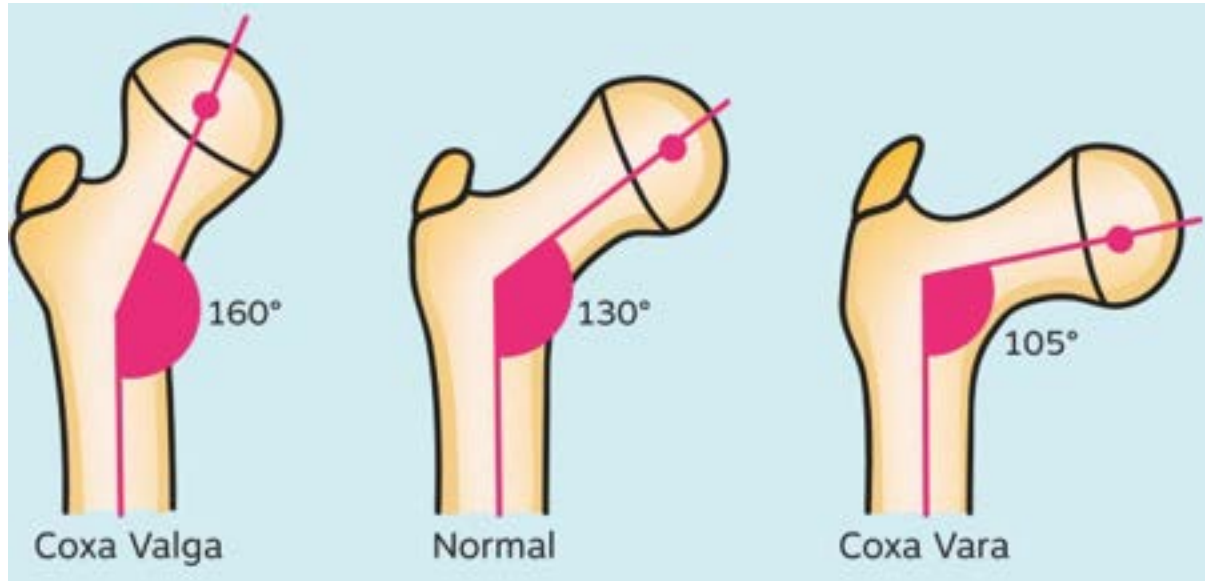
D. Coxa sultans

PyQ

neck-shaft

SNAPPING" HIP Sx
tendons





38. Identify the correct statements with respect to CTEV. py &

1. 50% cases are bilateral with male predominance

2. Forefoot is adducted and supinated

3. Ponsetti technique is preferred for correction

4. Adduction should be corrected first

A. 1, 2, 3, 4

B. 1, 2, 3

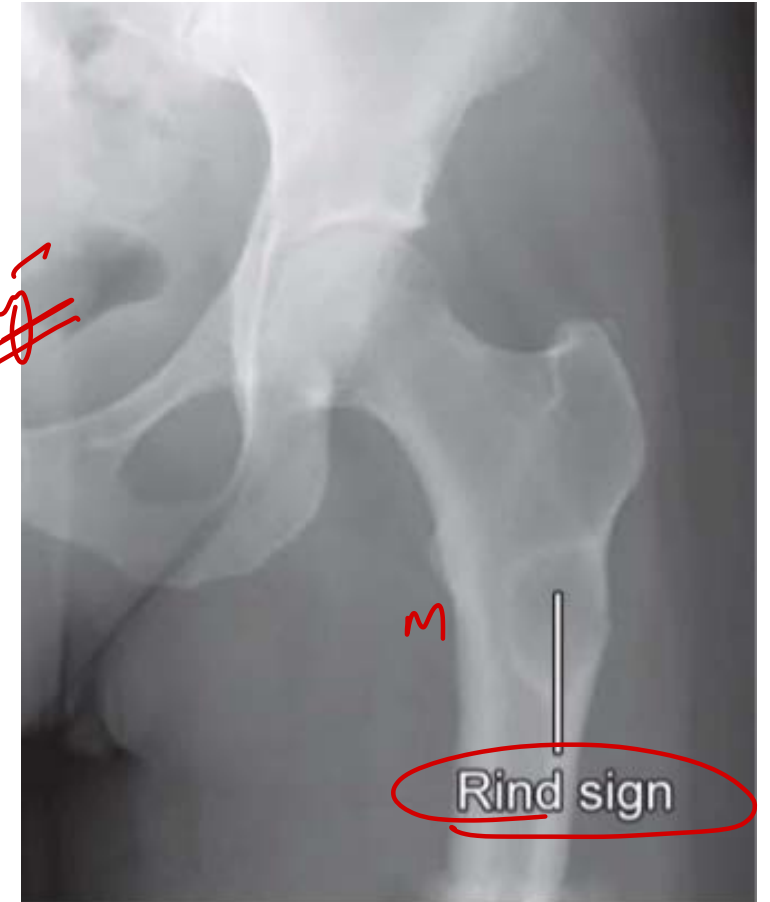C. 2, 3

D. 1, 4

~~X~~
CAVE
==

39. What is the likely diagnosis based in the given X-ray?

- A. ABC
- B. SBC
- C. Fibrous dysplasia
- D. Enchondroma

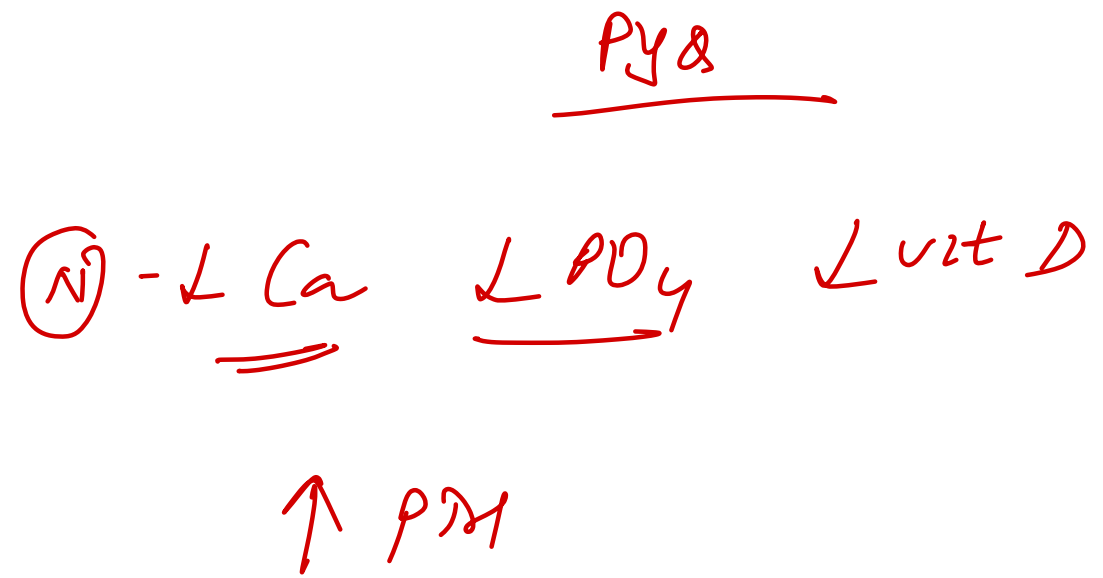


FD

40. Which of the following is incorrect about nutritional Rickets?

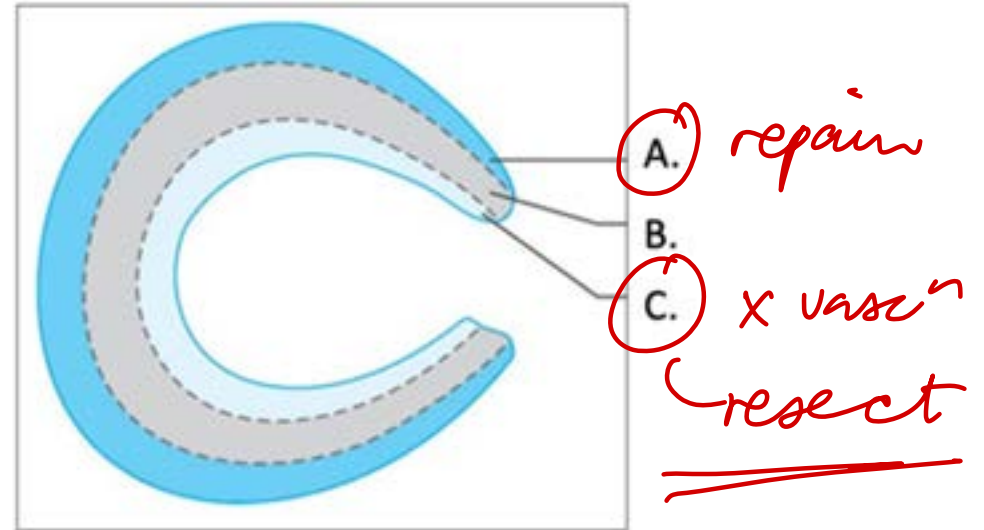
- A. Normal Serum Calcium
- B. High Parathyroid hormone
- C. Low Serum Phosphorus
- D. ~~High~~ Urine Calcium to Creatinine Ratio

↓



41. Resection is performed for tears in which of the following locations?

- A. A
- B. B
- ~~C. C~~
- D. Depends on morphology rather than location



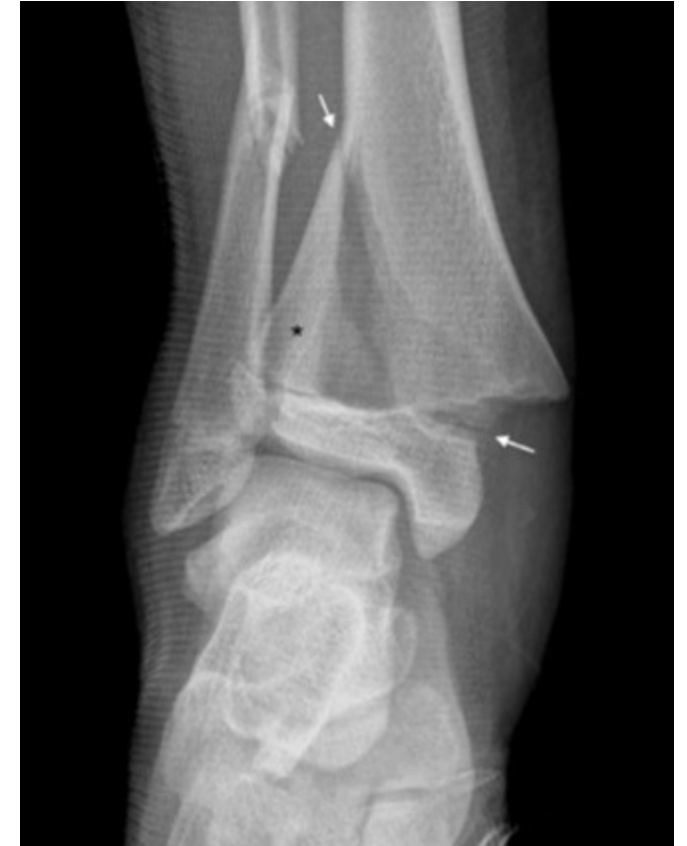42. Identify the type of Salter-Harris injury

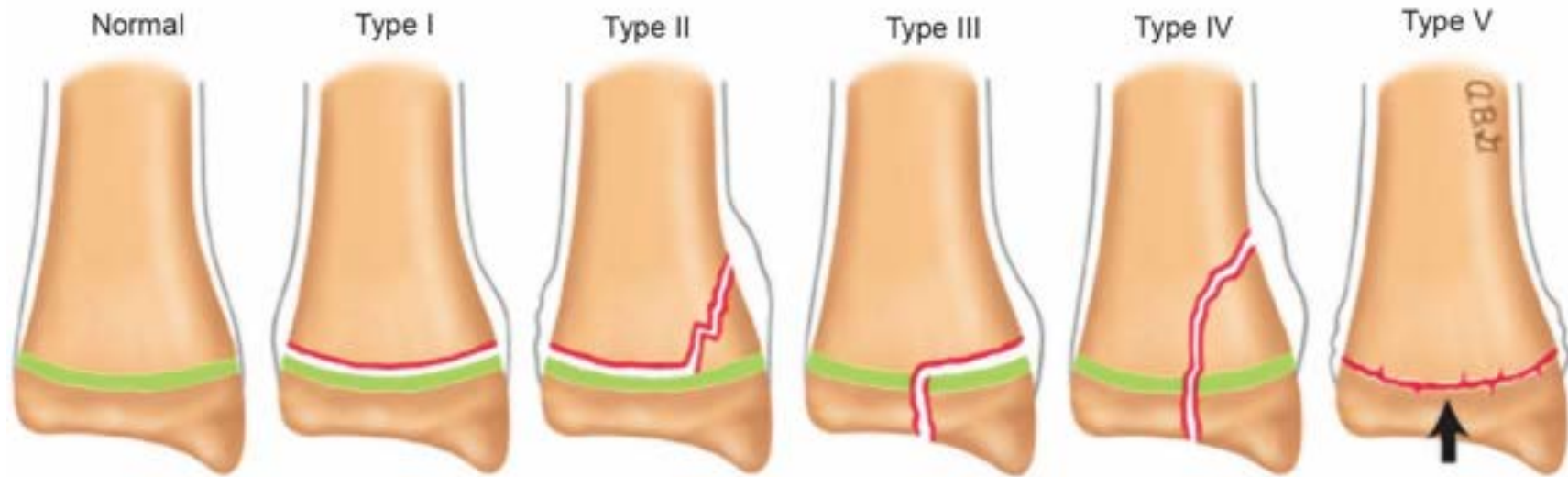
A. Type 1

B. Type 2

C. Type 3

D. Type 4





S

SCFE

A

SCH

L

Tillaux

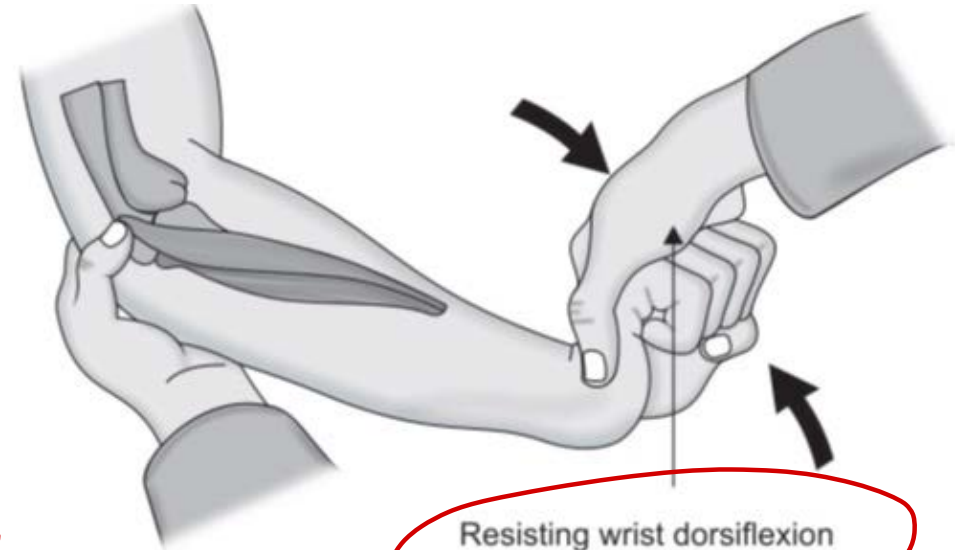
T

LCH

E R

43. The following test is useful for a diagnosis of?

- A. Golfer's elbow
- B. Carpal tunnel syndrome
- C. DeQuervian tenosynovitis
- ~~D. Tennis elbow~~



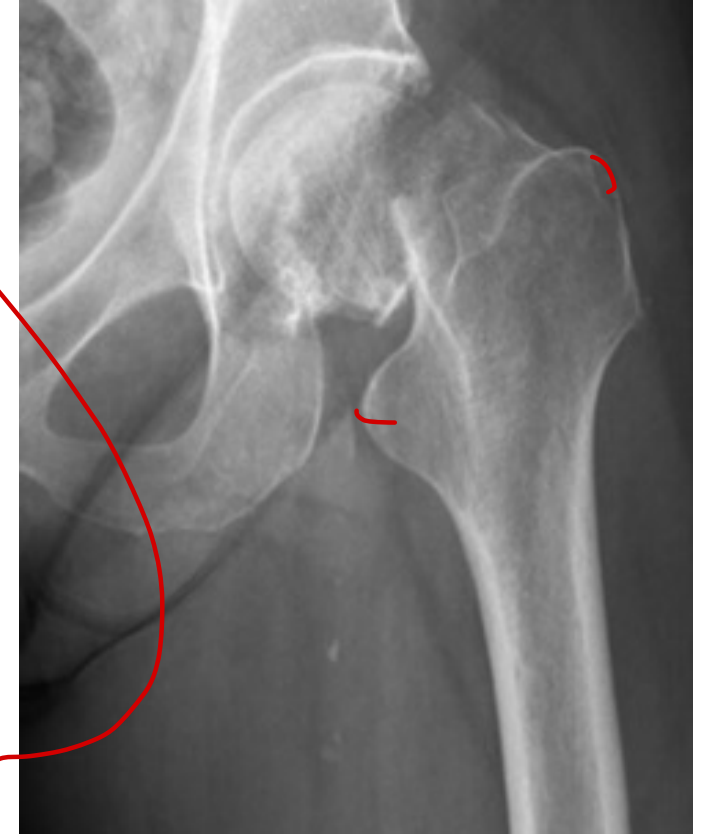tennis elbow

ECRB

Cozen test

44. A 45-year-old woman was taken to a trauma centre after suffering an accident. An X-ray of her pelvis was taken. In this instance, what is the management?

- A. Hemiarthroplasty
- B. Augmentation osteotomy
- C. Closed Reduction + Internal fixation
- D. Open Reduction + internal fixation



NOF
T
< 65yr
≥ 65yr

45. Identify the correct order of layers incised while performing a fasciotomy for compartment syndrome?

A. Skin and Subcutaneous tissue

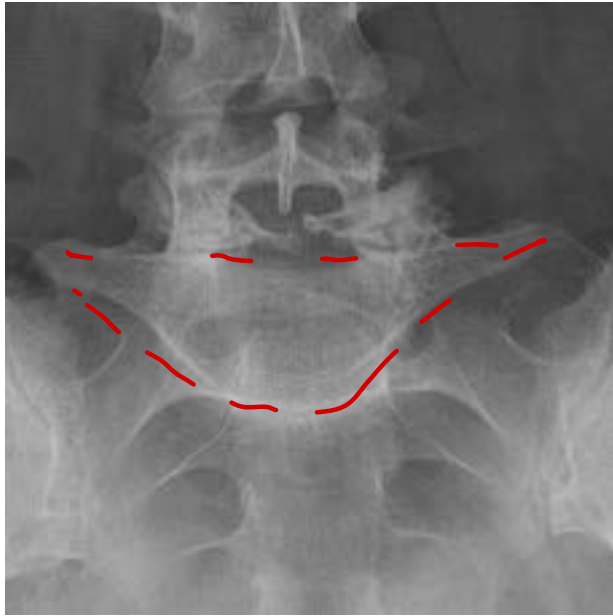
B. Skin, Subcutaneous tissue, Superficial fascia

C. Skin, Subcutaneous tissue, Superficial fascia and Deep fascia

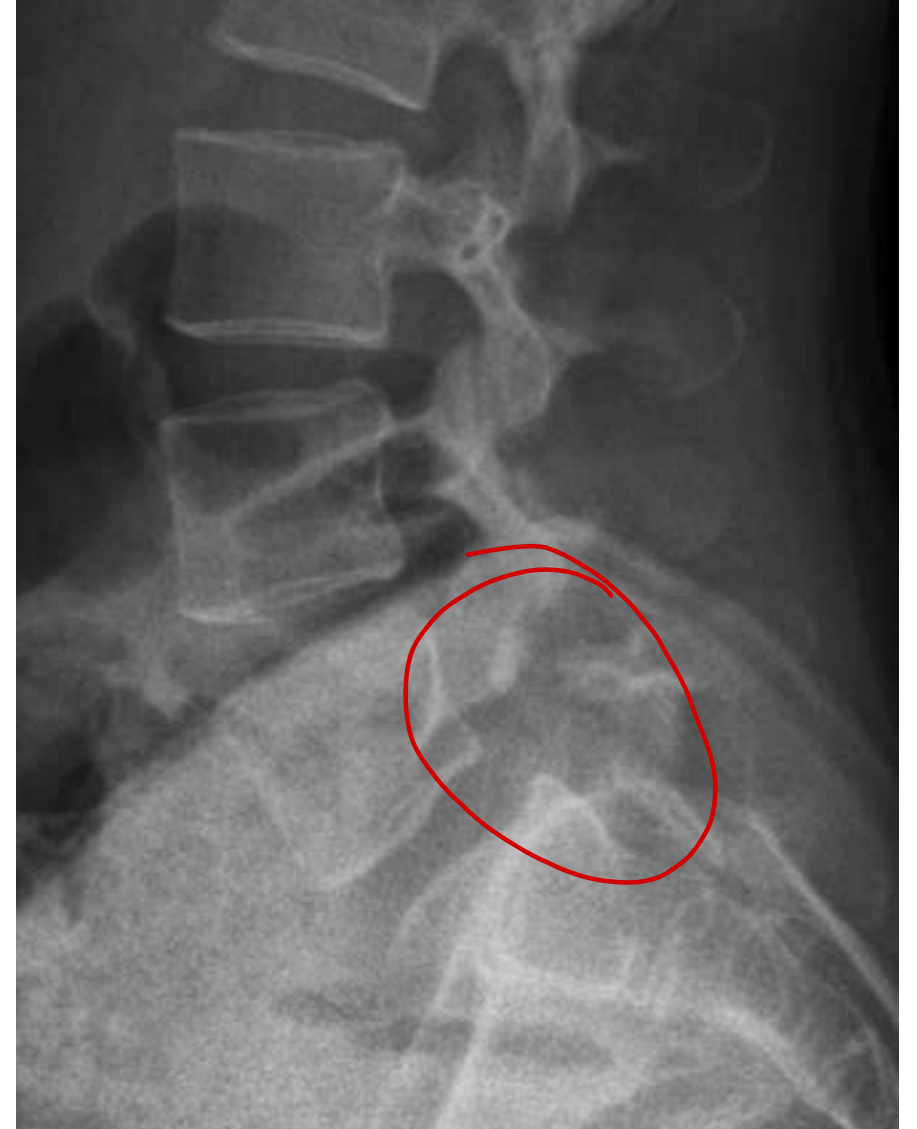
D. Skin, Subcutaneous tissue, Superficial fascia, Deep fascia and a few ~~muscular~~ fibers

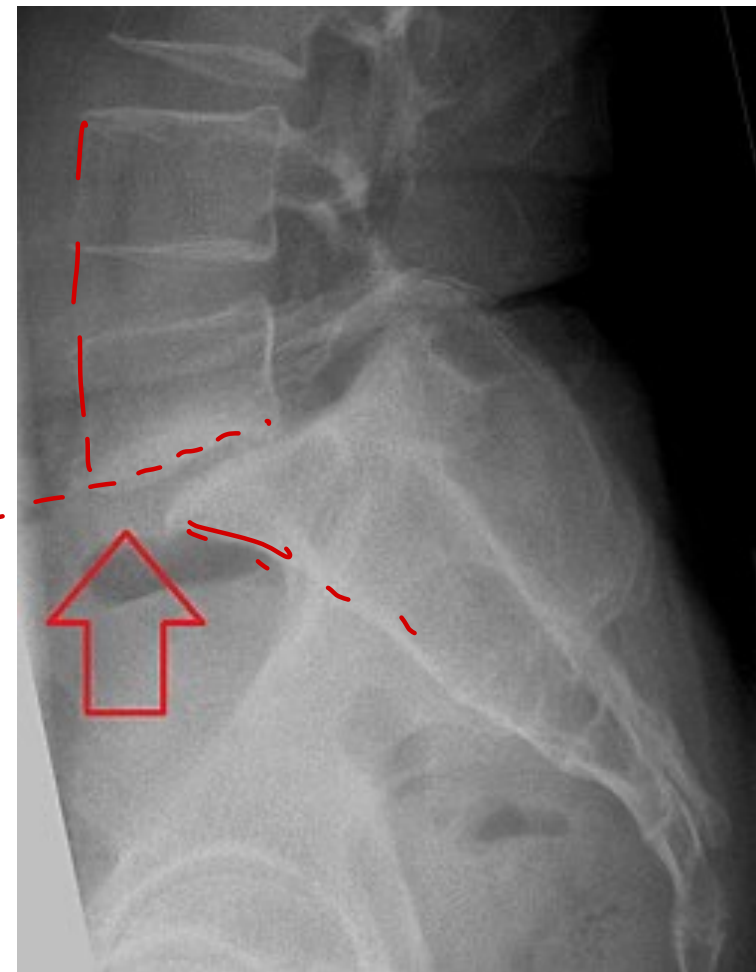
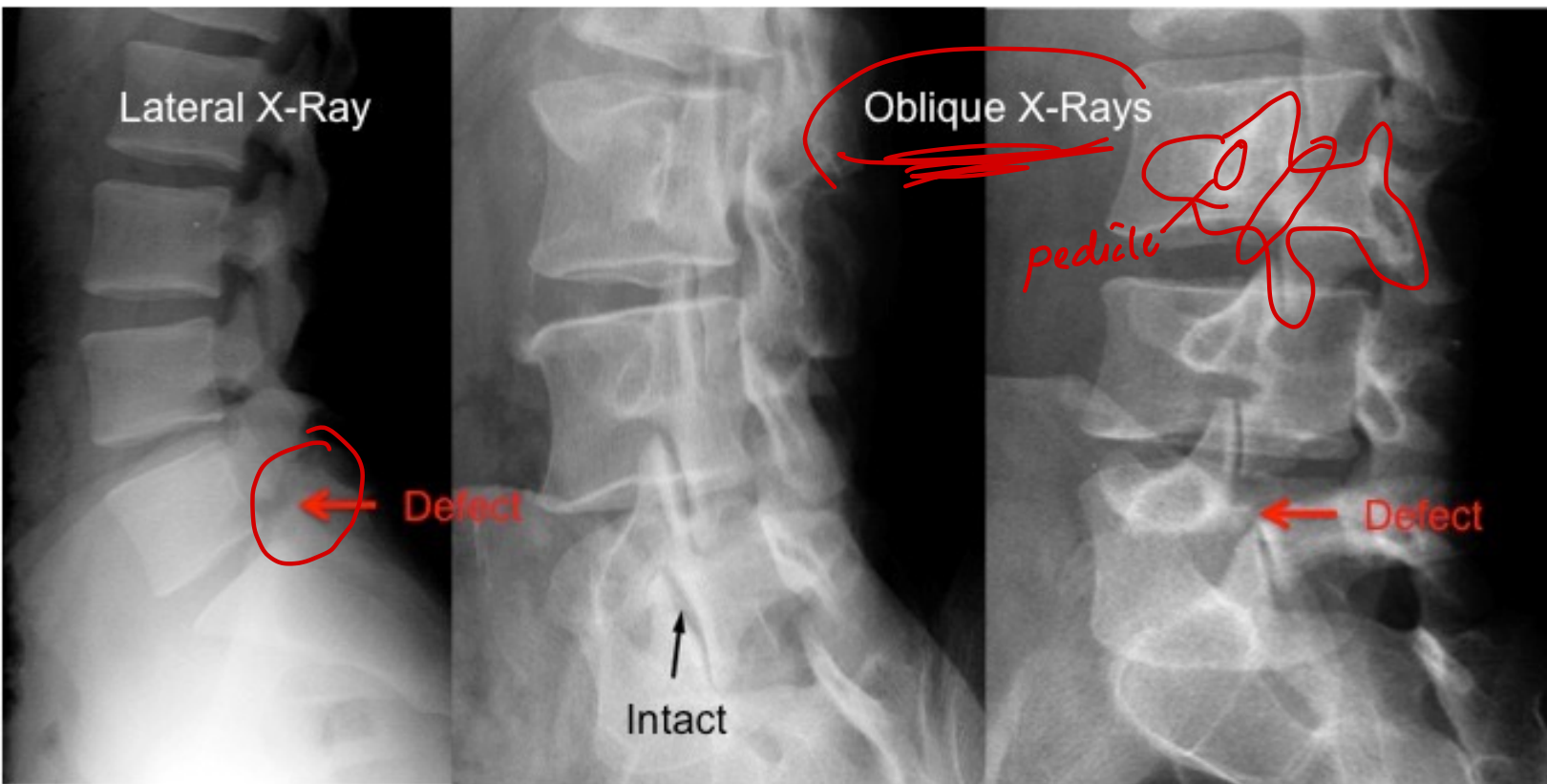
46. What is the diagnosis in the following radiograph?

- A. Chance fracture
- B. Spondylolisthesis
- C. Spondylolysis
- D. Ankylosing spondylitis



AP
Spondylolysis





pars interarticularis
 = I
 beheaded
 Scottish dog
 spindylolysis

Spondylolysis
 □
 ◡

47. Identify the incorrect statements

1. Tom smith arthritis most commonly affects the femoral capital epiphysis. (T)

septic - young - chondrolysis

2. De Quervain's tenosynovitis is the inflammation of the tendons of abductor pollicis longus and extensor pollicis brevis. (F)

3. Non-articular pain occurs only during ~~passive~~ movements.

4. Singh's Index is used for TB ~~grading~~.

active

A. 1, 2, 3, 4

~~B. 3, 4~~

C. 1, 3

D. 2, 3, 4

osteoporosis

Articular

- Deep or diffuse pain– both active and passive
- Swelling of joint, Crepitation, Joint instability, Locking of joint, Deformity

Non-Articular

labrum / tendon / rotator cuff

- Localised pain
- Painful active movements but not on passive

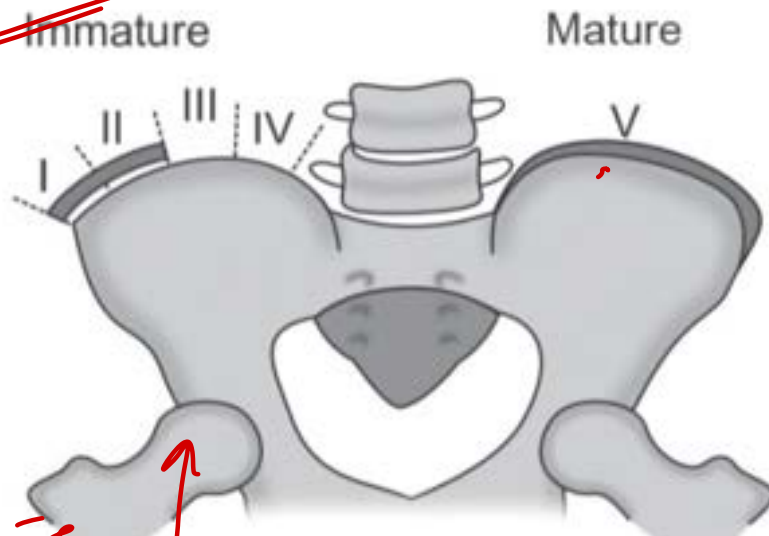
48. The index shown in the image below is useful for planning management of which condition?

- A. Scoliosis
- B. DDH
- C. Ankylosing spondylitis
- D. AVN

Sx

Cobb $\angle \rightarrow > 40^\circ$
Cobb \angle 30-40°
+
skeletal immature

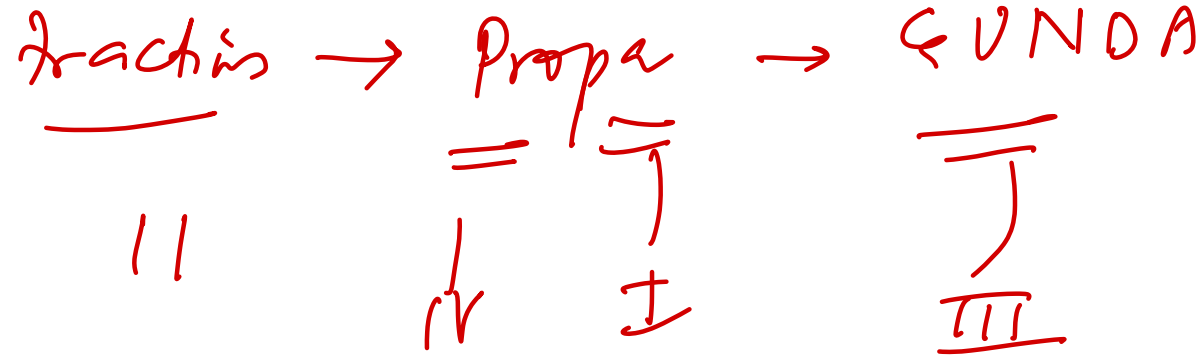
Risser



49. An orthopedic surgeon plans to treat a Colle's fracture. What are the steps involved in applying a cast for the same?

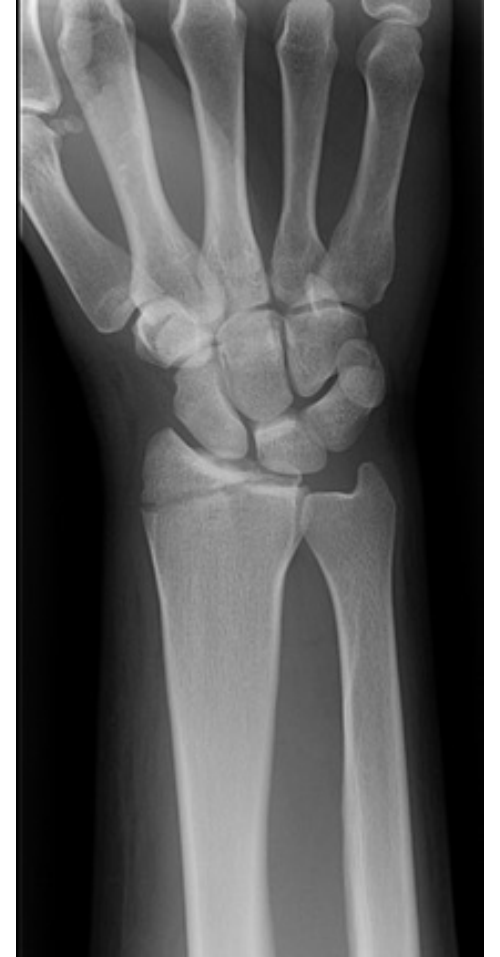- I. Palmar flexion
- II. Traction
- III. Ulnar deviation
- IV. Pronation

- A. I, II, III, IV
- B. I, II, IV, III
- C. II, I, III, IV
- D. II, IV, I, III



50. A 40-year-old man presents with wrist pain after a fall on an outstretched hand. The X-ray is shown below. What is the most likely diagnosis?

- A. Colles' ~~fracture~~
- B. Smith's ~~fracture~~
- C. Volar Barton's fracture
- D. ~~Chaffuer~~ fracture = Hutchison



51. A young female patient complains of low back pain radiating to the right hip, back of the thigh, leg, and ankle after an intense workout of lifting some heavy weights. MRI shows the following finding. Which function will be weak here?

- A. Hip flexion
- B. Ankle dorsiflexion
- C. EHL
- D. Ankle plantar flexion

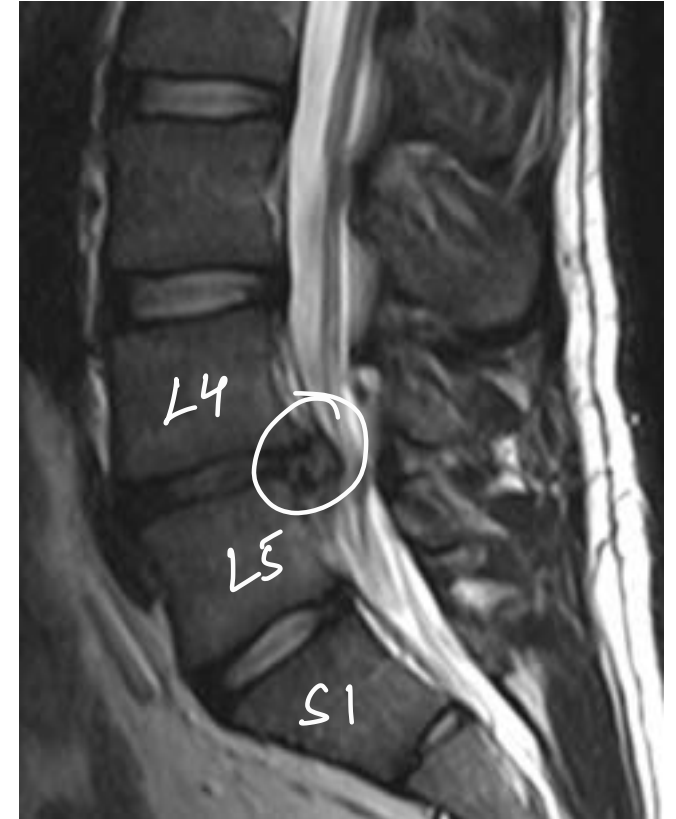
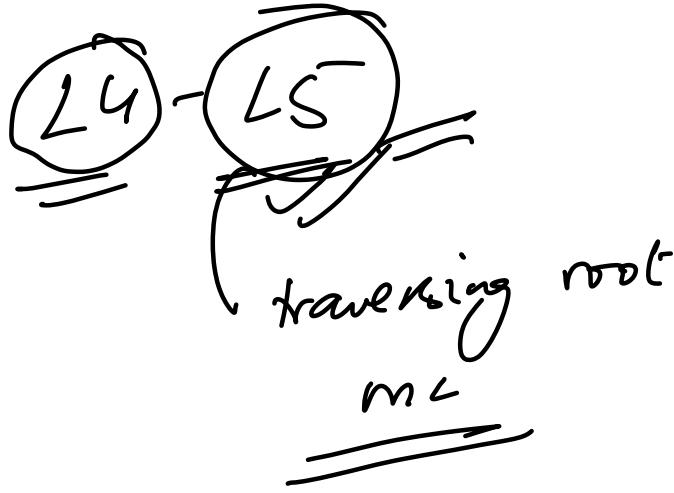


TABLE 37.2 Neurological evaluation of the upper limb.

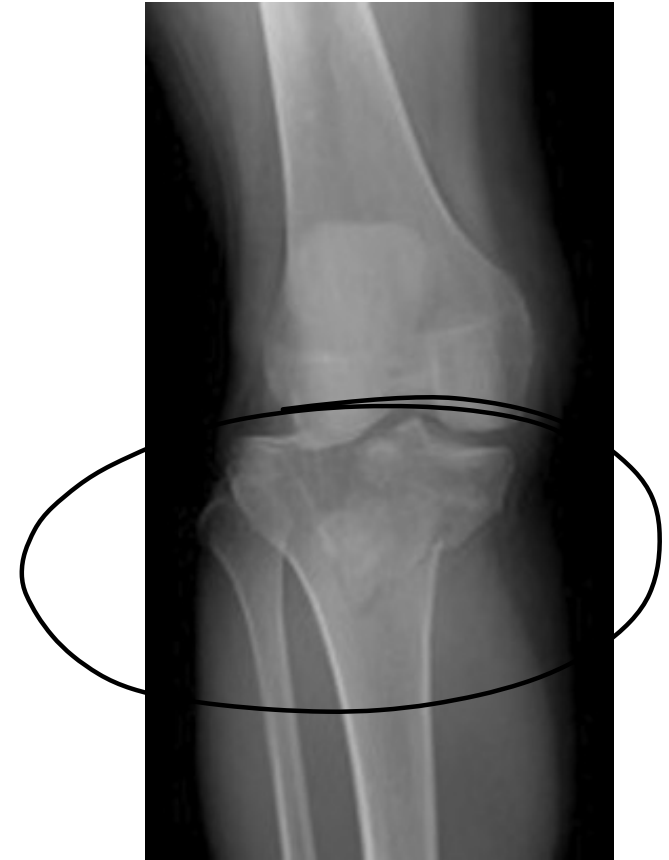| Neurological level | Motor | Sensation | Reflexes |
|--------------------|---------------------|-----------------|------------------------|
| C5 | Deltoid | Lateral arm | Biceps (C5/6) |
| C6 | Wrist extensors | Lateral forearm | Brachioradialis (C5/6) |
| C7 | Triceps | Middle finger | Triceps (C7/8) |
| C8 | Long finger flexors | Medial forearm | No reflex |
| T1 | Interosseus muscles | Medial arm | No reflex |

TABLE 37.3 Neurological evaluation of the lower limb.

| Neurological level | Motor | Sensation | Reflexes |
|---------------------------|--------------------------|-----------------------------|-----------------|
| L2 - <u>Hip flex</u> | Hip flexion | Anterior thigh, groin | No reflex |
| L3 - <u>knee ext</u> | Knee extension | Anterior and lateral thigh | Patellar (L3/4) |
| L4 - <u>ankle dorsifl</u> | Ankle dorsiflexion | Medial leg and foot | Patellar (L3/4) |
| L5 - <u>EHL</u> | Extensor hallucis longus | Lateral leg and foot | No reflex |
| S1 - <u>ankle plantar</u> | Ankle plantarflexion | Lateral foot and little toe | Achilles (S1/2) |

52. What is the correct classification for the following?

- A. Neer classification grade 4 → *Humerus*
- B. Ideberg classification grade 4 → *Glenoid*
- C. Sander classification grade 3 → *Calcaneum*.
- D. Schatzker classification grade 4



53. In a patient with Colles fracture, rupture of which tendon is most commonly seen?

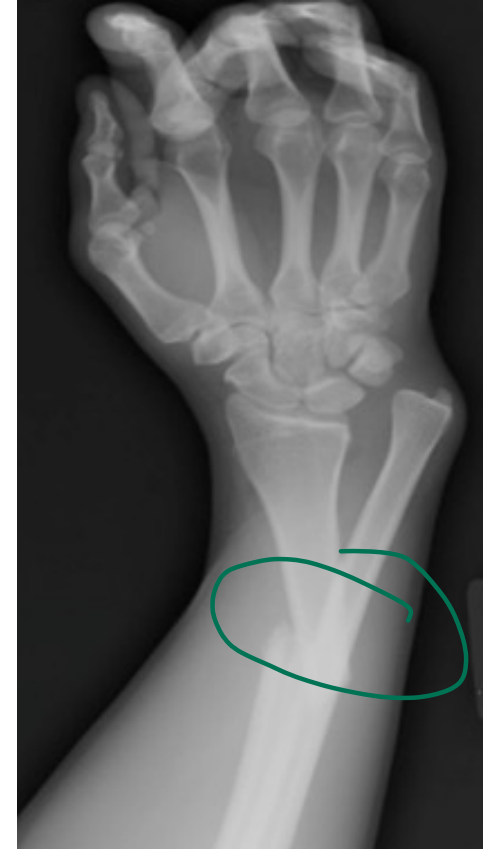- A. Extensor pollicis longus
- B. Extensor carpi ulnaris
- C. Abductor pollicis longus
- D. Extensor pollicis brevis

Pyq



54. What is the most appropriate treatment for the following fracture?

- A. External fixation with Ilizarov frame
- B. Closed reduction with below-elbow cast
- C. Internal fixation using compression plate
- D. Closed reduction with above-elbow cast



GRIMUS

Fractures of necessity



CR/OR

- Lateral condyle fracture humerus
- Displaced fracture of olecranon and patella
- Fracture neck of femur // CR-IF
- Galeazzi fracture-dislocation
- Monteggia fracture in adults
- Intra-articular fractures

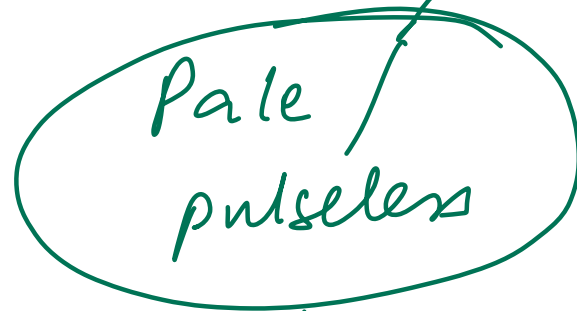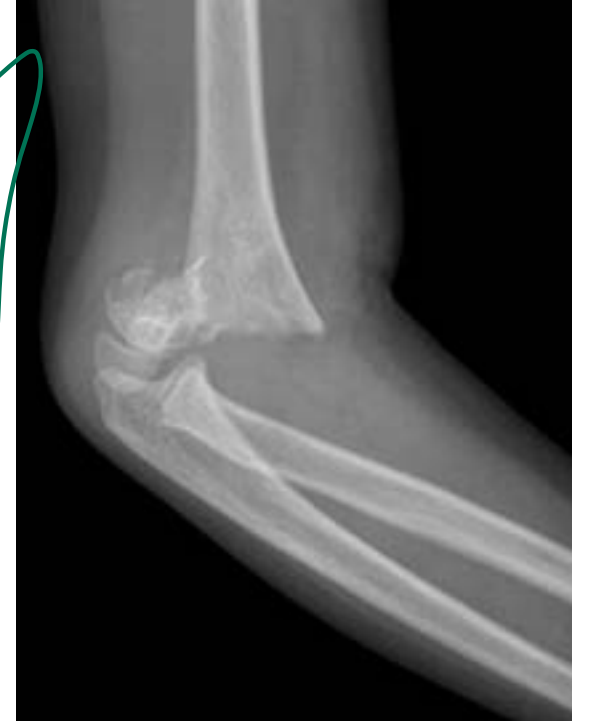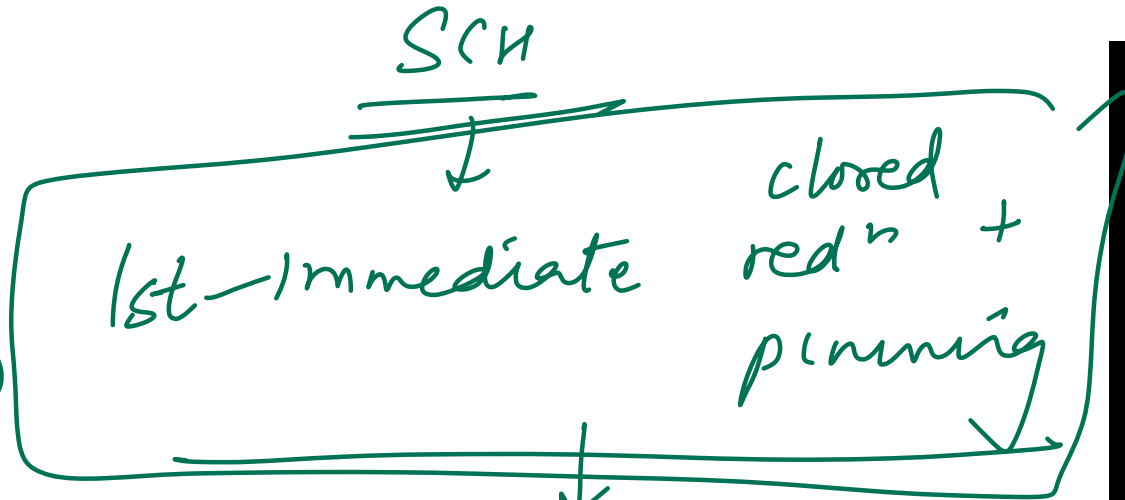
55. A 4-year-old presents with a pink but pulseless arm following an injury. Xray is shown below. What is the best next step? brachial A

A. Observation ~~XX~~

B. Vascular repair

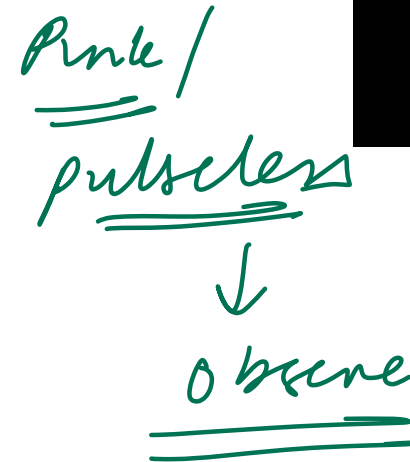
C. Fasciotomy ~~XX~~

D. Reduction and pinning



QQ

vascular repair



57. A 45 year old male patient sustained a tibial fracture was managed conservatively with a plaster cast. A few days later, severe pain was elicited on passive stretching. What is the indication of fasciotomy in this patient?

- A. Differential pressure less than 30 mmHg
- B. Differential pressure more than 30 mmHg
- C. Compartment pressure ~~less than 30mm Hg~~
- D. Diastolic blood pressure more than 100mm Hg

Comp pressure > 30m

$$\text{Differential} \downarrow \downarrow = \text{DBP} - \text{Comp pressure} \uparrow \uparrow$$

58. A 45-year-old man is brought to the emergency department following a motor vehicle collision. He reports right hip pain and numbness along the right thigh. Physical examination shows decreased sensation to light touch over a small area of the medial thigh. X-rays of the pelvis show a displaced pelvic ring fracture. Further evaluation of this patient is most likely to show which of the following findings?

- A. Sensory deficit of the dorsal foot
- B. Impaired hip extension
- C. Impaired dorsiflexion of the foot
- D. Impaired adduction of hip**

obturator N

59. A 41-year-old woman comes to the doctor because of gradually progressive weakness in her right hand over the past few weeks. She goes to the gym to lift weights 5 times a week. With the dorsum of the right hand on a flat surface, the patient is unable to move her thumb to touch a pen held 2 cm above the interphalangeal joint of the thumb. An MRI of the right arm shows compression of a nerve that passes through the pronator teres muscle. Based on the examination findings, loss of innervation of which of the following muscles is most likely in this patient?


A. Adductor pollicis *ulnar N*

~~B. Abductor pollicis brevis *median N (all thenar)*~~

C. Extensor pollicis brevis

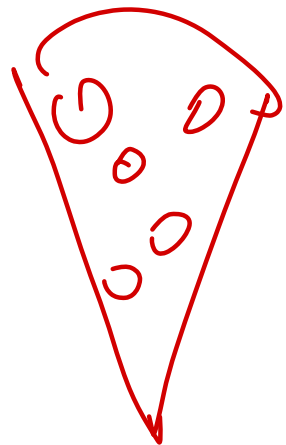
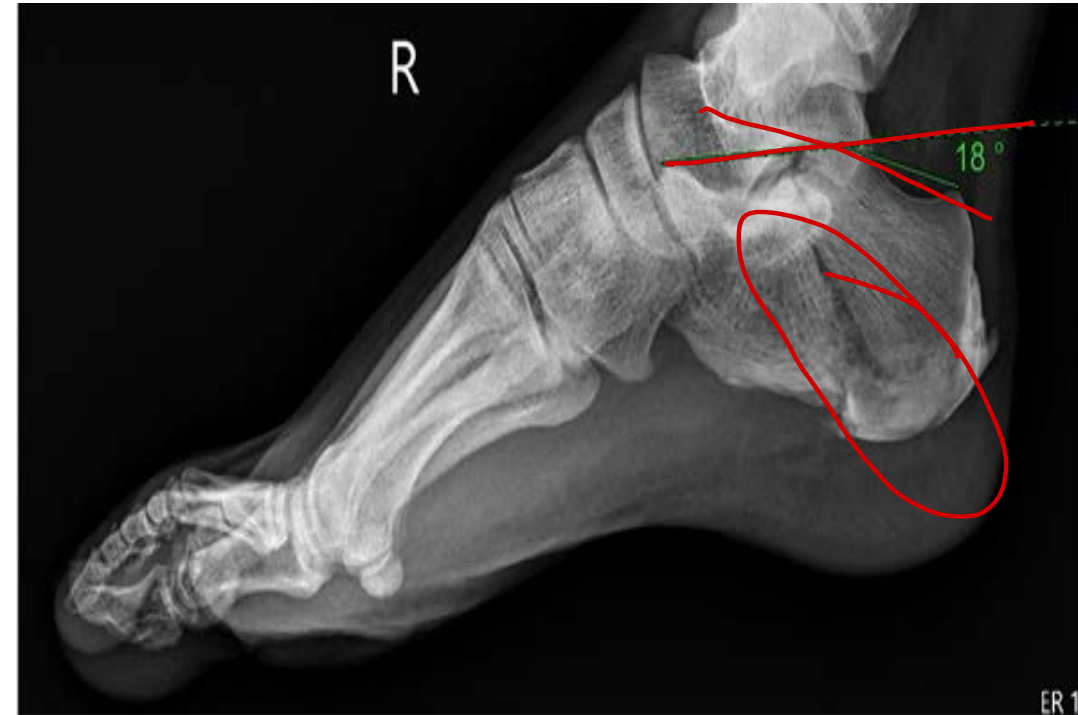~~D. Abductor pollicis longus~~ *radial N*

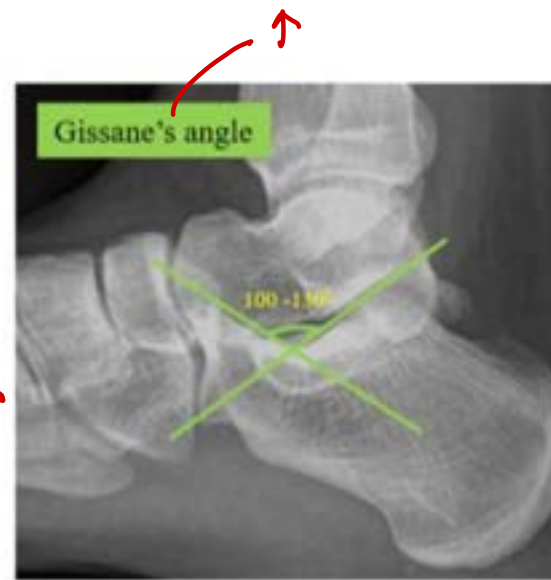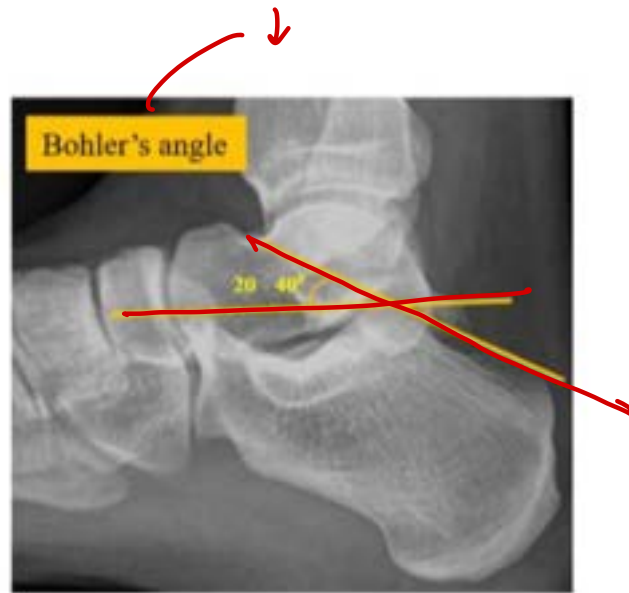
PM
median N



60. A patient presents with left heel pain following a fall from a ladder. A lateral radiograph of the left foot is shown. What is the most likely diagnosis?

- ~~A. Calcaneal fracture with reduced Bohler angle~~
- B. Calcaneal fracture with increased Bohler angle
- C. Calcaneal fracture with reduced Gissane angle
- D. Calcaneal fracture with increased Gissane angle

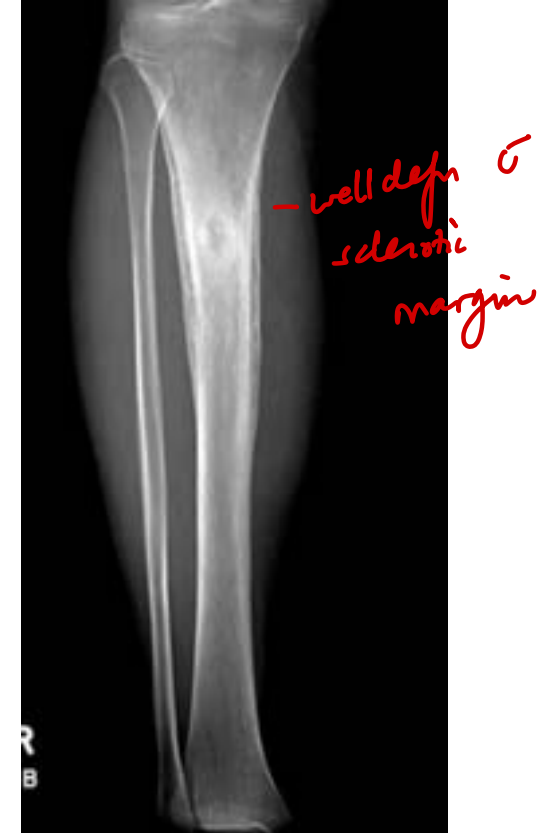



61. A 15-year-old male with pain and swelling gradually increasing over 4 months at the upper end of tibia. What is the likely diagnosis?

- A. Osteoclastoma ~~XX~~
- B. Ewing sarcoma =
- C. Brodie abscess
- D. Osteosarcoma ~~XX~~

FMGE J by



62. 6-year-old boy is brought to the OPD for evaluation of back pain. The pain has been constant for the last 2 weeks and keeps the patient from playing with his friends. He wakes up several times nightly to void and has had episodes of incontinence as the leg pain prevents him from walking to the bathroom. Which of the following is the most likely diagnosis in this patient?

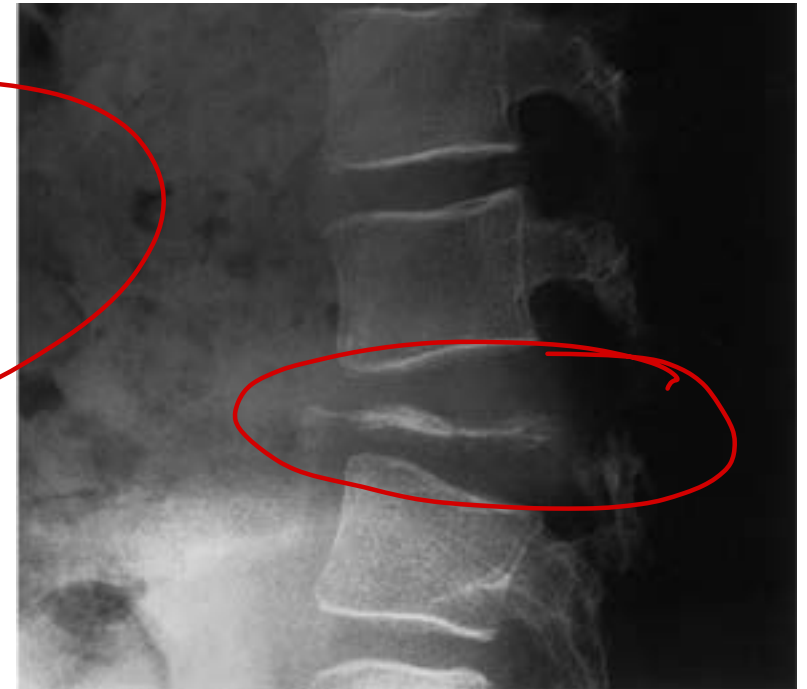
- A. Langerhans cell histiocytosis
- B. Ewing sarcoma
- C. Mazabraud syndrome ~~XX~~
- D. McCune Albright syndrome ~~XX~~

DI

+ vertebral plana

+

skin lesions



63. 6-year-old girl is brought to the clinic for evaluation of knee pain. The patient first had soreness in her right knee 4 days ago, after her first gymnastics class. Her mother gave her PCM and massaged her knee, but this did not help. The patient also developed a limp over the past 2 days. She has no chronic medical conditions and does not take daily medications. Height is at the 50th percentile and weight is at the 90th percentile. Temperature is 37.9 C (100.2 F). When walking, she limits weight-bearing on her right side. When supine, the right hip is held flexed with the knee pointed laterally. There is limited internal rotation and extension of the right hip. The right knee has full range of motion and there is no tenderness on palpation around the knee. Laboratory evaluation shows leukocyte count of 11,500/mm and C-reactive protein of 8 mg/L (normal: <10). Ultrasound of the hips shows small, bilateral effusions. Which of the following is the most likely diagnosis in this patient?

- A. Juvenile idiopathic arthritis ~~XX~~ - multiple Jt chronic >6wks
- B. Perthes disease ~~XX~~
- C. Slipped capital femoral epiphysis ~~XX~~
- D. Transient synovitis

HIP

Septic arthritis

↑ fever / ↑↑ CRP ESR

64. All of the following are susceptible to AVN except:

A. Proximal pole of scaphoid

B. Neck of talus

C. Head of femur

D. Head of humerus

#

body talus

AVN

65. 10-year-old girl with Down syndrome is brought to the clinic due to behavioural changes. Over the past month, she has stopped running, tripped frequently while walking, and accidentally knocked toys over more often than normal. The patient was toilet-trained at age 4, but recently she began having frequent urinary accidents while playing and has started wearing a diaper again. Physical examination shows an ataxic gait. Bilateral ankle deep tendon reflexes are hyperreflexic. When the soles of the feet are firmly stroked the big toes move upward and the other toes fan out. Urinalysis is normal. Which of the following is the most likely cause of this patient's presentation?

A. Early onset Alzheimer-disease *JMN*

B. Atlantoaxial instability

C. Hypothyroidism *XX*

D. Spinal cord infarction

AAD *JMN*

DC DC
ASA

66. A 42-year-old woman comes to the office for evaluation of a mass at her right wrist. The patient first noticed swelling in her wrist a few months ago after spending a week knitting blankets for her family. Medical conditions include hyperlipidemia and rheumatoid arthritis. The mass is firm, mobile, and nontender to palpation, and it transilluminates on penlight examination. Which of the following is the most likely diagnosis in this patient?

A. Epidermoid cyst ~~XX~~

B. Ganglion cyst

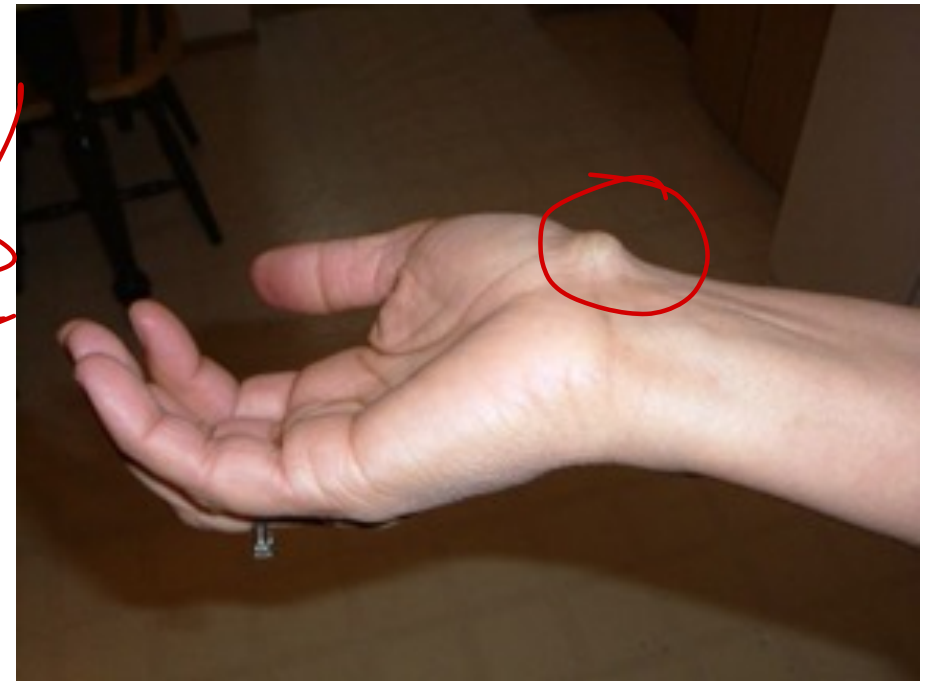C. Lipoma ~~X~~

D. Rheumatoid nodule ~~XX~~



→ spont resolⁿ

→ aspirin /
IGD



67. A 40-year-old man comes to the emergency department due to worsening right lower abdominal pain that radiates to the right groin area. Two weeks ago, he was treated for furunculosis of the right thigh. The patient has a history of type 1 diabetes mellitus and takes insulin. Abdominal examination shows tenderness on deep palpation in the right lower quadrant without rebound or guarding. No masses are palpated. Bowel sounds are present. Extension of the right hip increases pain, and flexion decreases pain. Which of the following is the likely diagnosis?

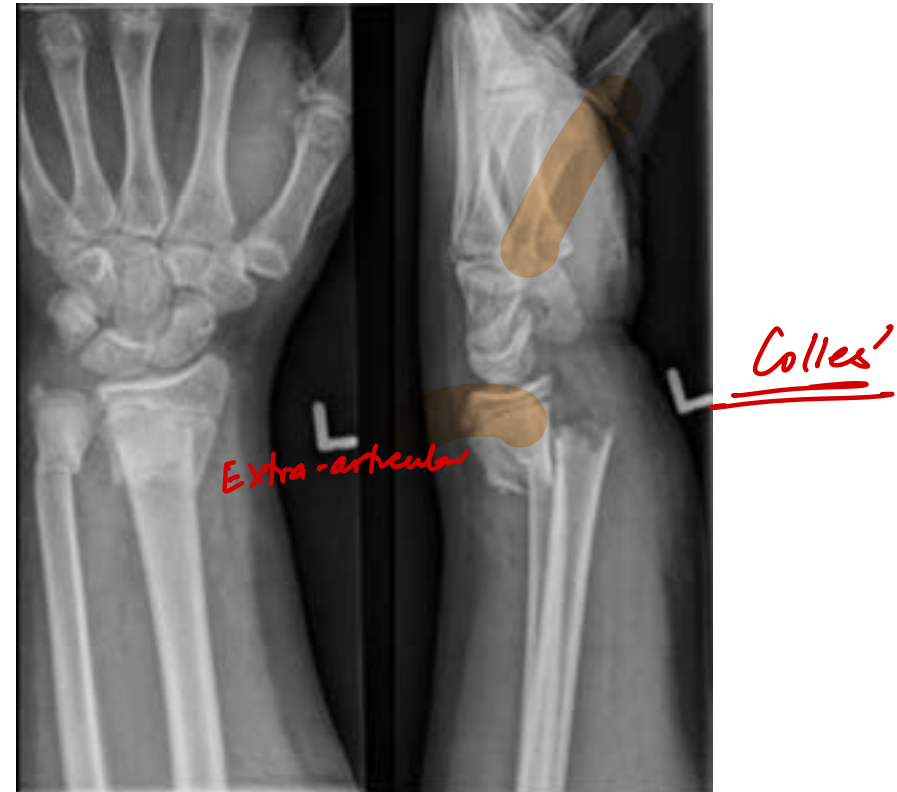
- A. Acute appendicitis ~~XX~~
- B. Psoas abscess
- C. Small bowel obstruction
- D. Acute pancreatitis

68. A 45-year-old man comes to the emergency department due to left wrist pain after a fall. The patient was walking in his house when he tripped over a rug and landed on his outstretched hand. Medical history is notable for celiac disease, hypertension, and hypothyroidism for which he takes appropriate daily medications. X-ray of the left wrist is shown below. Which of the following is the most significant risk factor for bone fracture in this patient?

- A. Age X
- B. Celiac disease
- C. Hypertension X X
- D. Hypothyroidism

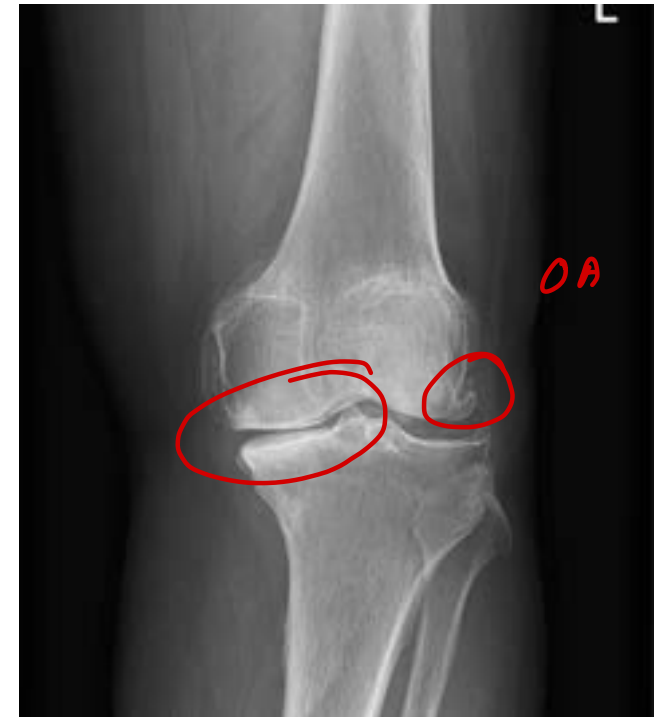Congenital
epiphyses X

Vit D ↓
A D E K
fat



69. 61-year-old man comes to the OPD due to chronic left knee pain. The pain is worse when he first gets out of bed in the morning and is associated with mild stiffness. On examination, the left knee has a small effusion and mild pain over the medial and lateral joint lines. There is no clicking or locking of the knee, but crepitus is present with range of motion. The patient is able to bear weight without pain and the joint is stable to varus and valgus stress. X-ray of the knee is shown in the image below: Which of the following is the most appropriate initial treatment for this patient's knee pain?

- A. Methotrexate ~~RA~~ *RA*
- B. Corticosteroid injection of the knee ~~XX~~ *-acute*
- C. Knee replacement surgery ~~XX~~
- D. ~~✓~~ Quadriceps strengthening exercises



70. 26-year-old man with a history of seizure disorder and medication nonadherence is hospitalized after a generalized tonic-clonic seizure. A witness reports that the patient lost consciousness and fell to his right side; the seizure lasted about 2 minutes. Evaluation in the emergency department reveals a low serum level of his prescribed antiepileptic drug, levetiracetam, and a displaced right femur fracture. Levetiracetam is restarted and the patient undergoes intramedullary nailing of the fracture with no intraoperative complications. The next day the patient is noted to be confused. Temperature is 37.2 C (99 F), blood pressure is 142/86 mm Hg, pulse is 102/min, and respirations are 28/min. Oxygen saturation is 90% while breathing room air. On physical examination, the patient is disoriented but has no focal weakness or sensory loss. There are no skin rashes or hematoma at the surgical site. CT pulmonary angiography shows bilateral scattered ground-glass opacities but no filling defects within the pulmonary vasculature. Which of the following is the most likely cause of this patient's current condition?

- A. Aspiration pneumonitis
- B. Cardiogenic pulmonary edema
- C. Drug-induced hypersensitivity reaction
- D. Fat embolism

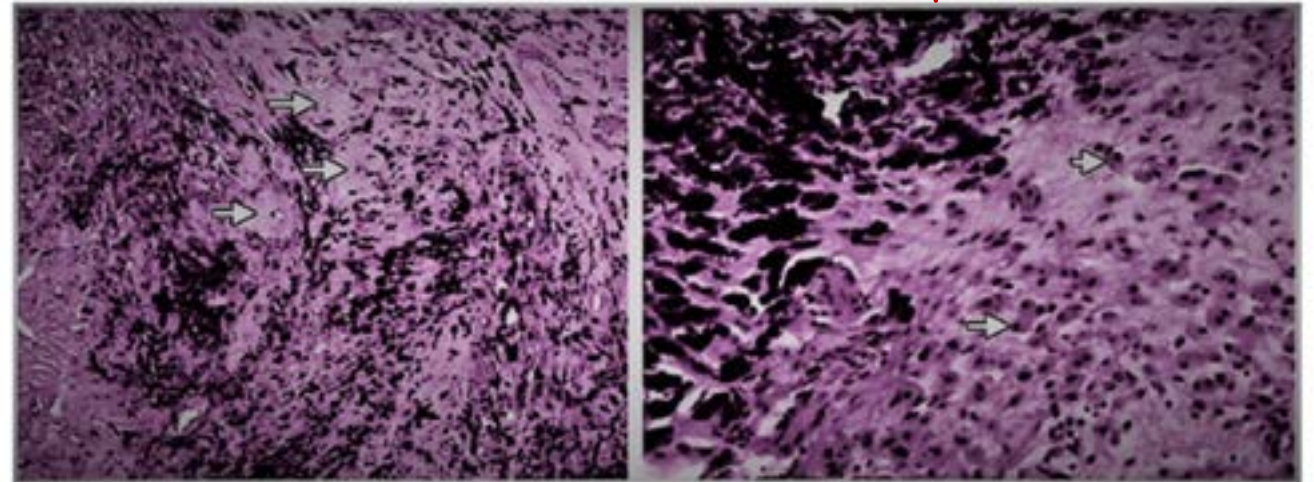
#7

NGET 25
→ 28 hrs ✓
✓

71. A 60 year old female underwent hip replacement. After 1 year she developed fever and pain in the joint. Radiograph revealed loosening of prosthesis. The implant had to be removed. The histological image of the tissue adjoining the implant is show below. What is the diagnosis?

Pyo

- A. Metallosis
- B. Melanoma x
- C. Ochronosis x
- D. Rosai Dorfmann Syndrome f



72. The following pelvic X-ray was seen in a patient. All the following signs will be present except:

A. Ortolani sign ✓

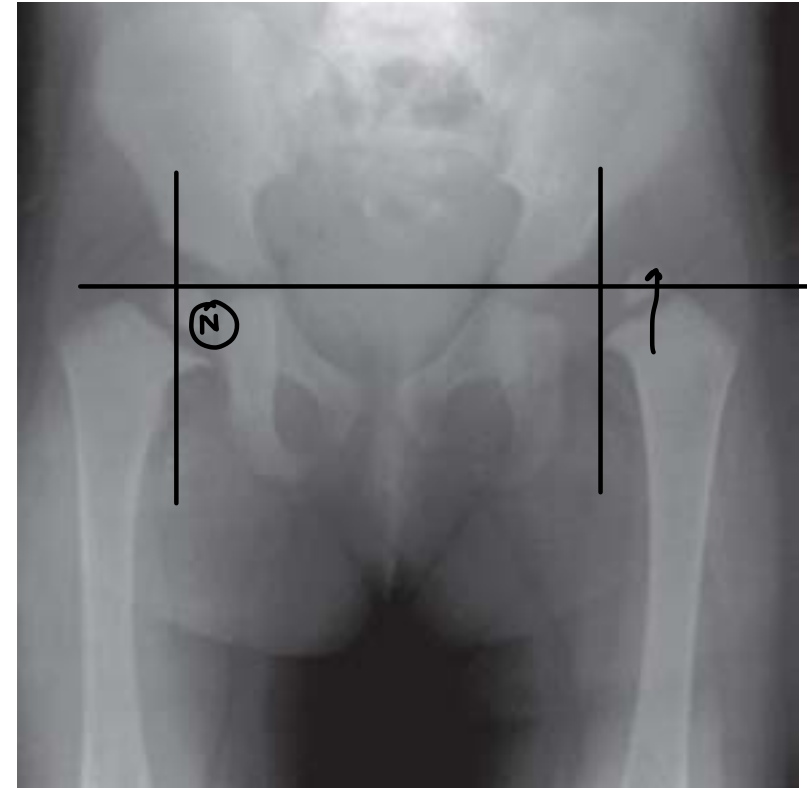
B. Barlow sign ✓

C. Narath sign ✓

D. Gaenslen sign

telescoping (+)

SI jt
dysplasia



LE DDH

73. A 6-year-old girl is evaluated for early-onset puberty and multiple bone lesions. On examination, she has café-au-lait spots as shown below. Hormonal tests confirm hyperfunction of multiple endocrine glands. What is the underlying genetic mutation in this condition?

A. NF1 gene ~~X~~

B. GNAQ gene mutation

C. GNAS gene mutation

D. FGFR3 ~~X~~

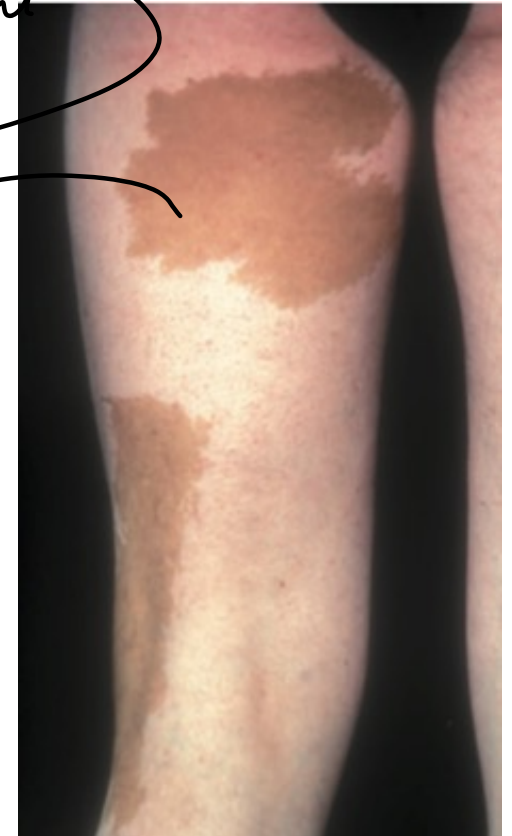achondroplasia

-Sturge Weber

FD

McCune Albright

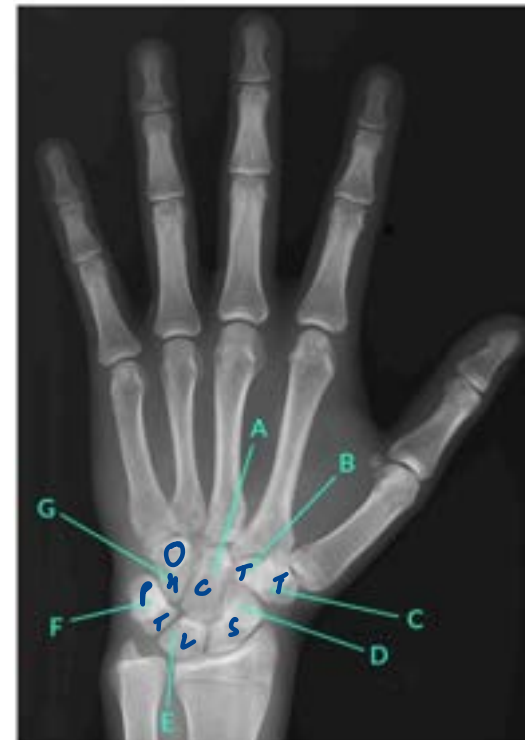CALM
Maurie



74. A 19-year-old man comes to the physician because of episodic tingling and numbness in his right hand for the past 3 weeks. He says that he cannot hold a pen very well and that this is affecting his handwriting. Sensation to light touch is decreased over the right little finger and the medial palmar surface of the right hand. Radiologic evaluation in this patient is most likely to show a fracture in which of the following bones?

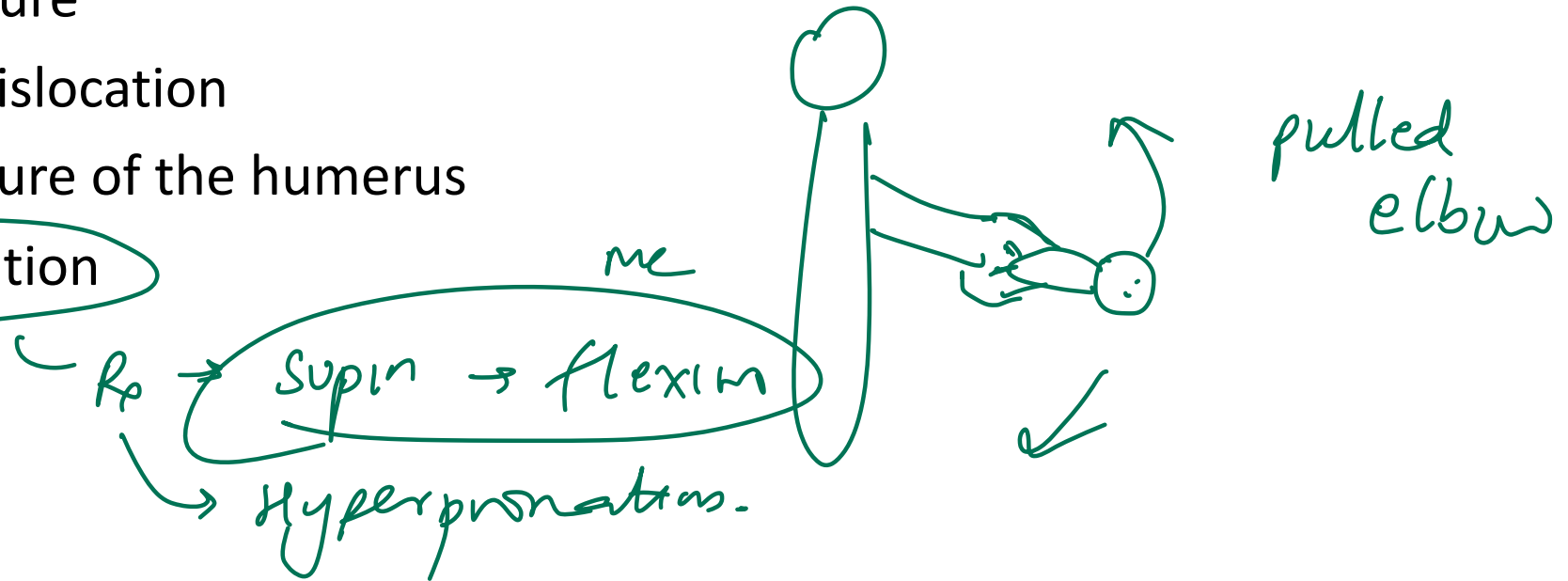
- A. A
- B. C
- C. D
- D. G**

Ulnar N



75. A previously healthy 2-year-old boy is brought to the emergency room by his mother because of persistent crying and refusal to move his right arm. The episode began 30 minutes ago after the mother lifted him up by the arms. He appears distressed and is inconsolable. On examination, his right arm is held close to his body in a flexed and pronated position. Which of the following is the most likely diagnosis?

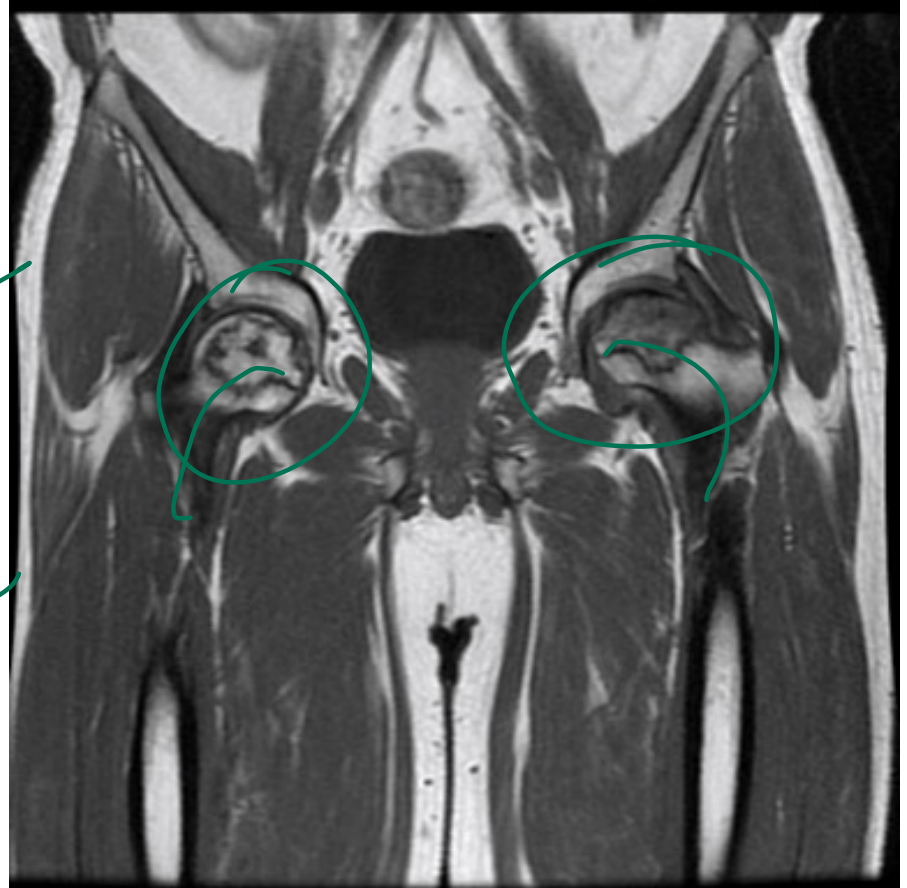
- A. Proximal ulnar fracture
- B. Anterior shoulder dislocation
- C. Supracondylar fracture of the humerus
- D. Radial head subluxation**



76. The following condition develops due to which vessel?

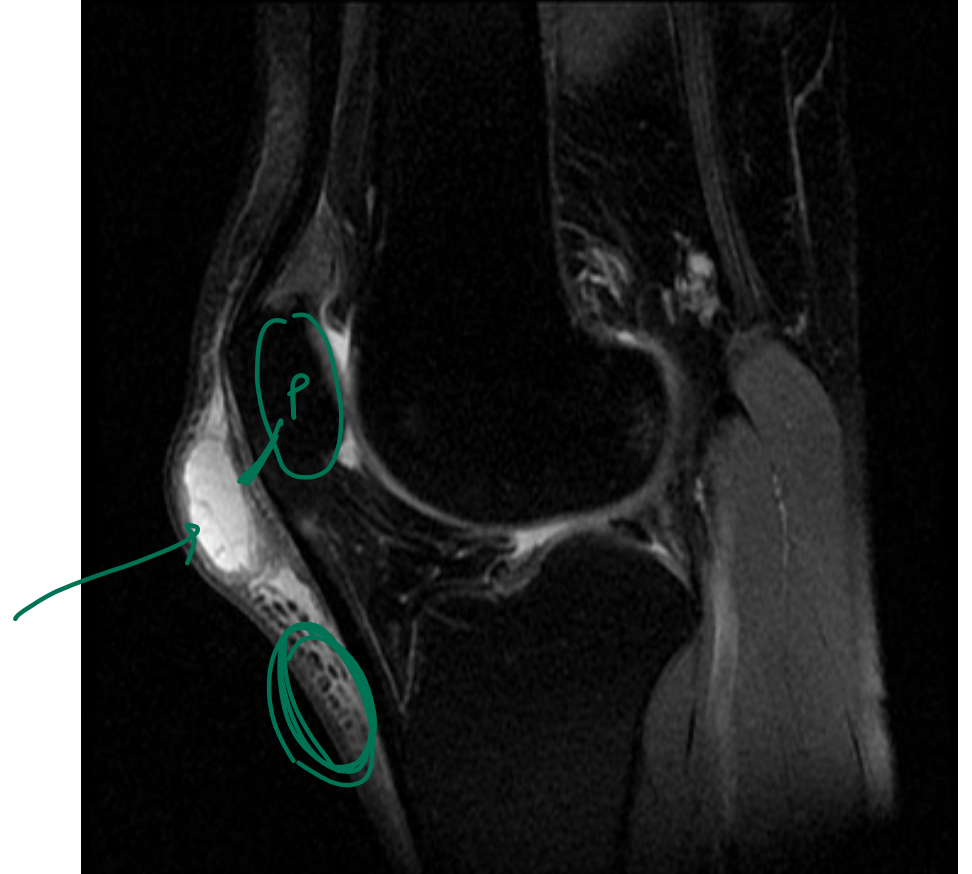- A. Medial circumflex femoral artery
- B. Lateral circumflex femoral artery
- C. Obturator artery
- D. Profunda femoris artery

AVN
MRI 100



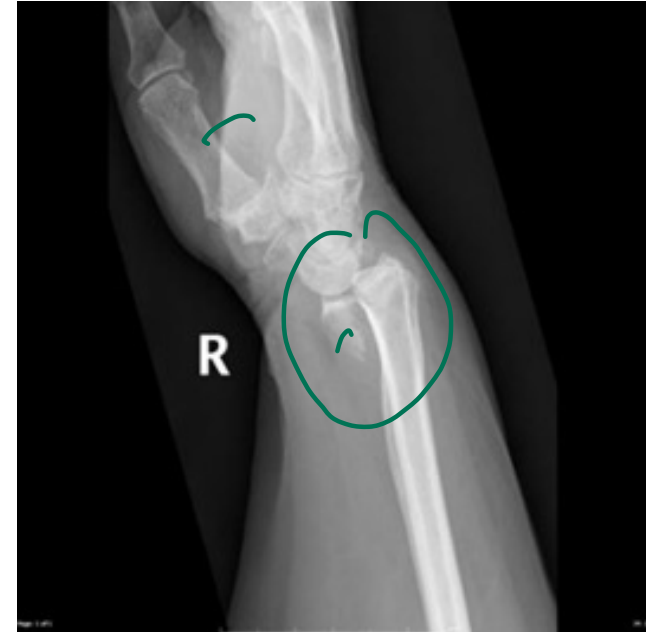77. A 42-year-old female complains of soft, fluctuating swelling in front of the knee. She reports discomfort and difficulty while moving her knee. MRI is shown below. What is the most probable diagnosis?

- A. Cleryman's knee *- infrapatellar*
- B. Housemaid's knee**
- C. Gout *xy*
- D. Pes anserinum bursitis



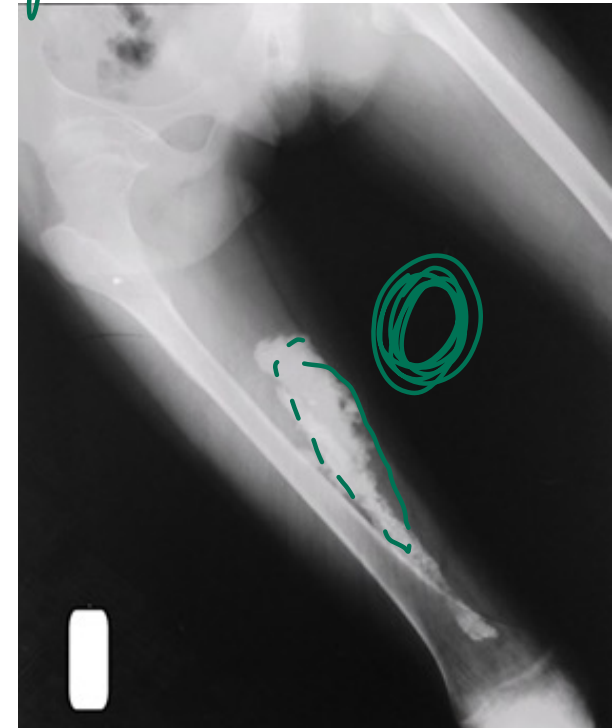
78. A 40-year-old man presents with wrist pain after a fall on an outstretched hand. The X-ray is shown below. What is the most likely diagnosis?

- A. Colles' fracture
- B. Smith's fracture
- C. Volar Barton's fracture
- D. Scaphoid fracture



79. A 19-year-old male patient comes to the clinic for follow-up 3 weeks after a traumatic fracture in his right thigh. On examination, he was found to have a hard palpable mass near the fracture site. X-ray of the area shows the findings below. A histological section shows central fibrous tissue and mature bone at the periphery. Which of the following is true about this patient's diagnosis?

- A. Parosteal osteosarcoma
- B. Myositis ossificans
- C. Osteochondroma
- D. AV fistula



80. Identify the incorrect statement about Seddon classification of nerve injuries:

- A. No loss of nerve sheath continuity in Neurapraxia and axonotmesis
- B. Wallerian degeneration is not seen in neurapraxia
- C. Surgical intervention is always needed in neurotmesis
- ~~D. Nerve regrowth happens at ~~3mm~~ per day~~ *1mm/day*

Seddon classified nerve injuries into neurapraxia, axonotmesis and neurotmesis:

- **Neurapraxia** – no loss of nerve sheath continuity or peripheral Wallerian degeneration. If the pressure is removed from the nerve, recovery potential is good but may take months.
- **Axonotmesis** – nerve sheath remains intact, with internal nerve fibre damage and associated Wallerian degeneration. The neural tube (endoneurium) can guide the regenerating nerve fibres to their target. Good potential for recovery; nerve fibre regrowth is at 1 mm per day.
- **Neurotmesis** – complete division of the nerve, nerve sheath and nerve fibre. Functionally poor outcome without surgical intervention to restore continuity of the nerve sheath.

Sunderland

| Degree | Pathology | Previously Called |
|--------|--|------------------------|
| 1 | Blocked flow of axoplasm / conduction block | Neuropraxia |
| 2 | Loss of axons but within its endoneurium | Axonotmesis |
| 3 | Loss of endoneurium and crossed regeneration | Neurotmesis |
| 4 | Injury to <u>perineurium</u> and scarring | Partial transection |
| 5 | Injury to <u>epineurium</u> and scarring | Complete transection |



Cerebellum
Get the balance right

Thank you

Best wishes!